

第64回日本臨床細胞学会秋期大会

第5回唾液腺細胞診症例検討会

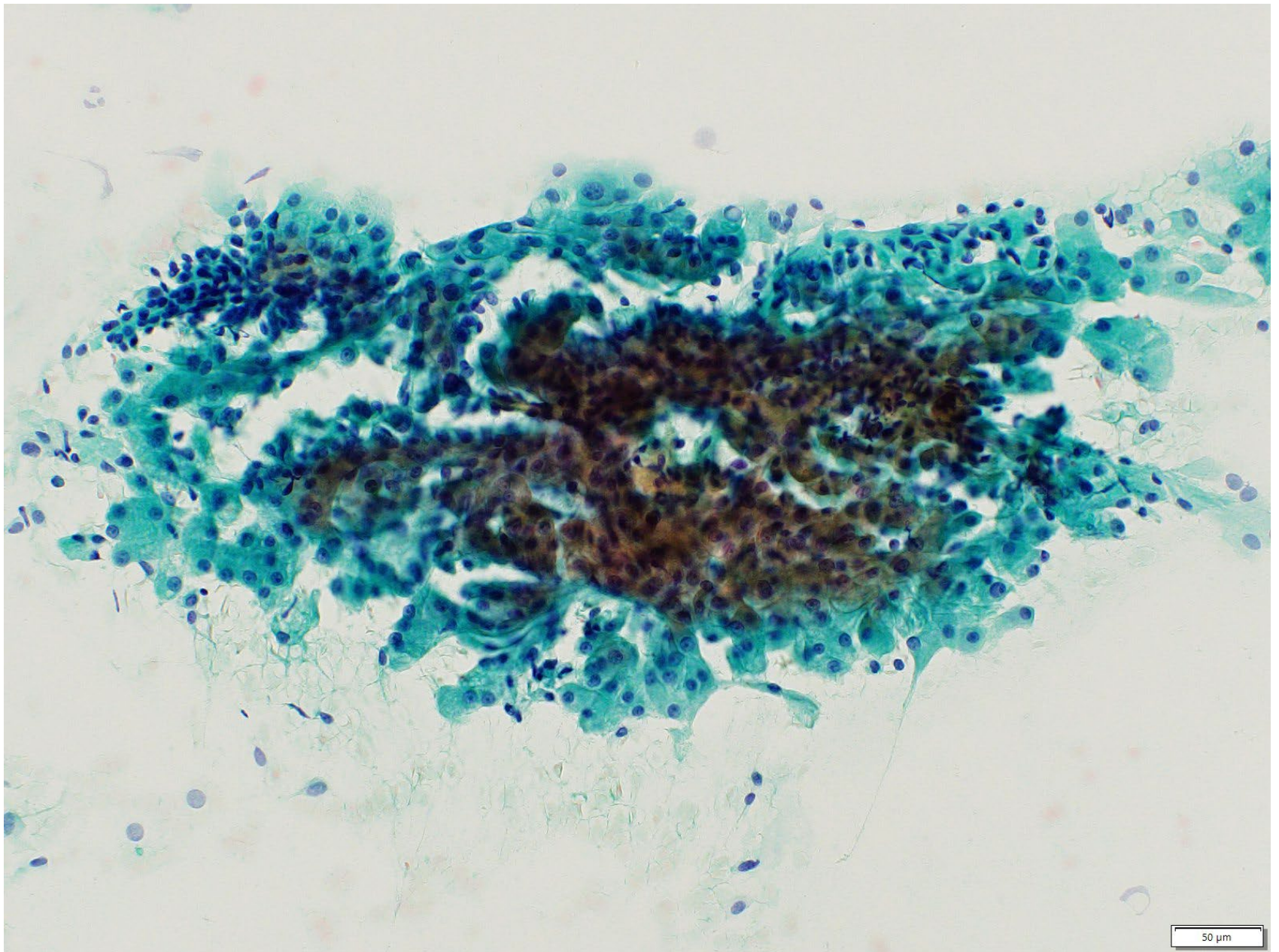
沖縄協同病院病理診断科
琉球大学非常勤講師

樋口佳代子

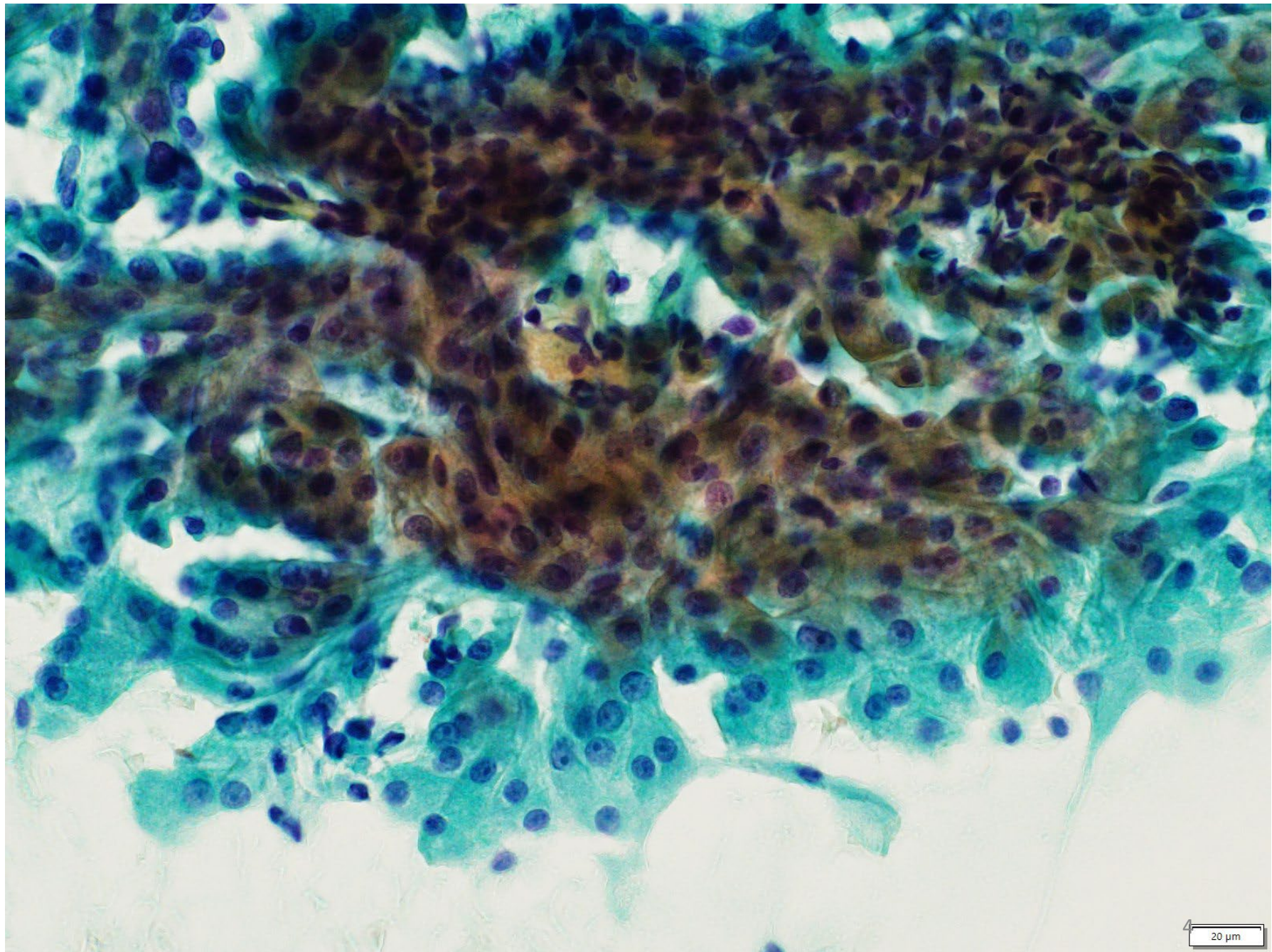
2025.11.29 於 広島国際会議場

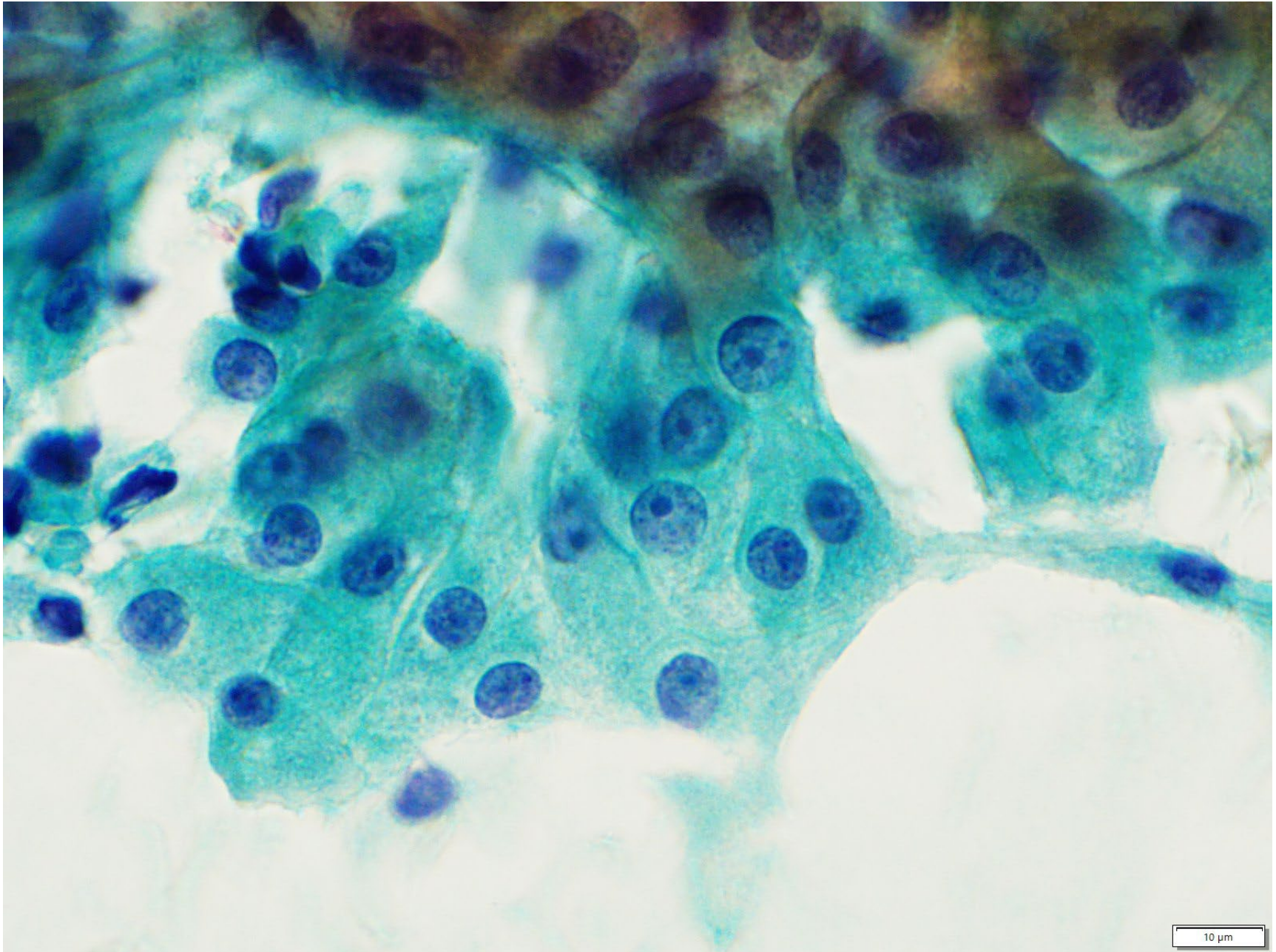
症例 1

50歳、男性、右耳下腺穿刺

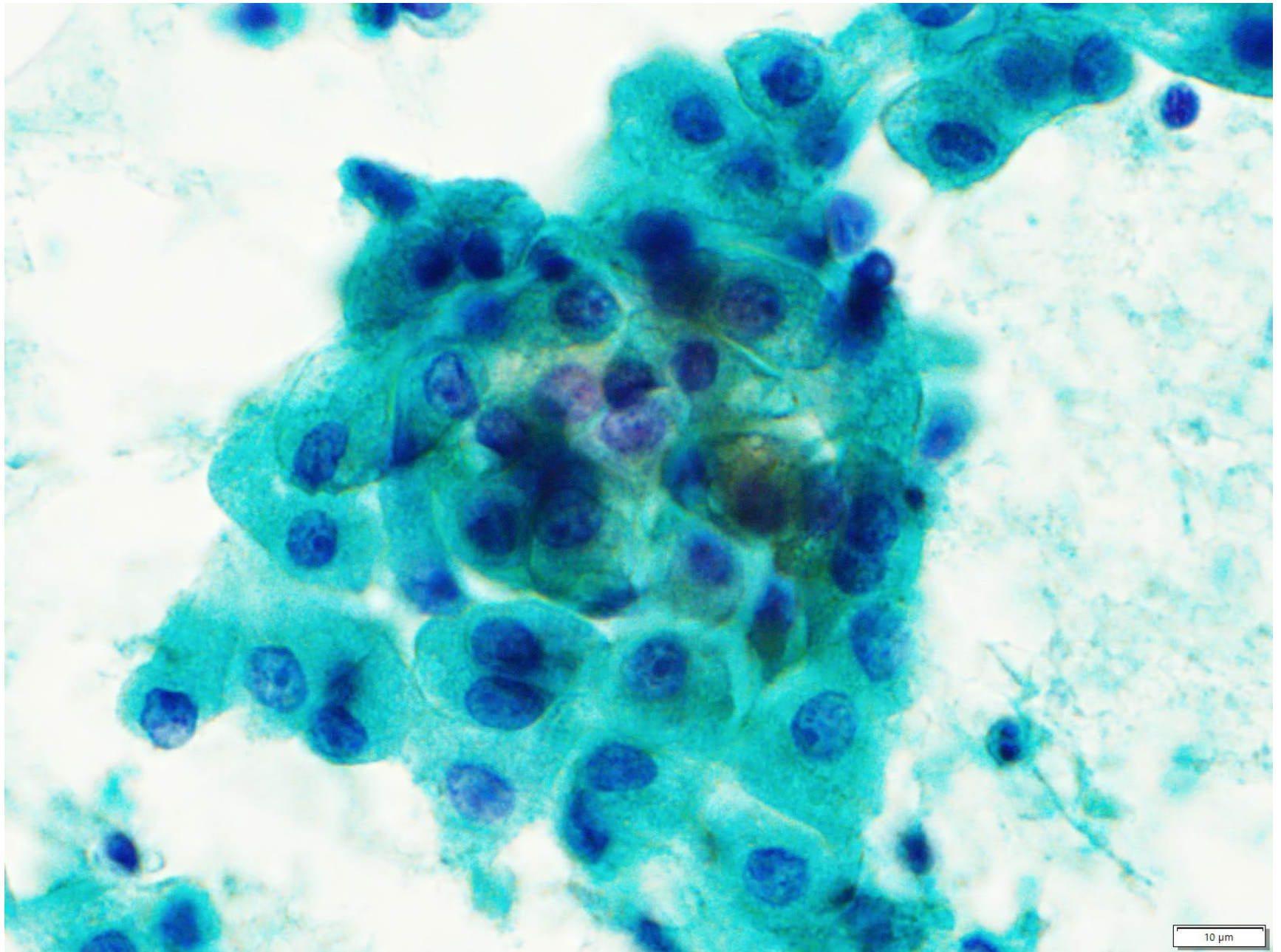


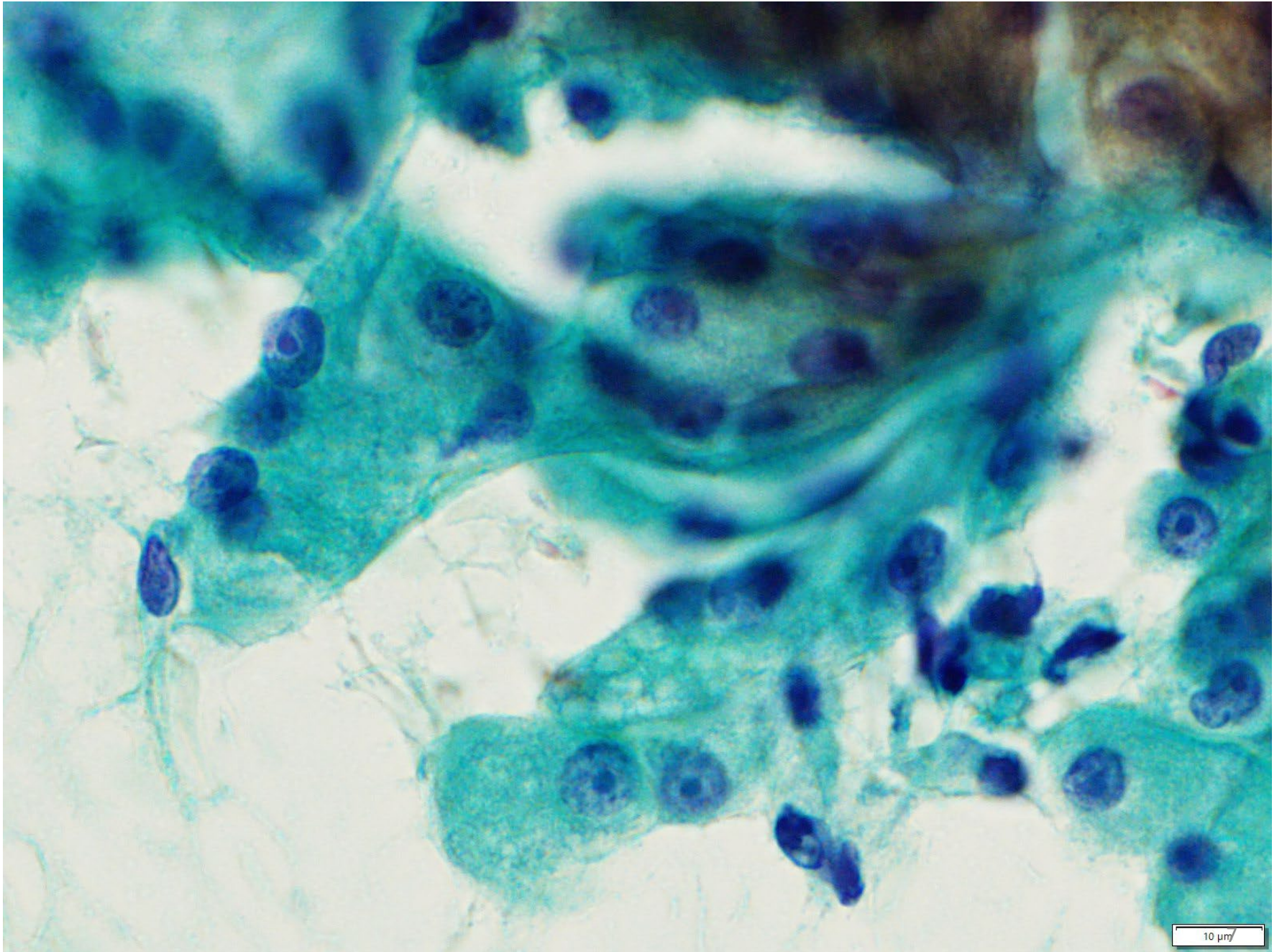
50 μ m

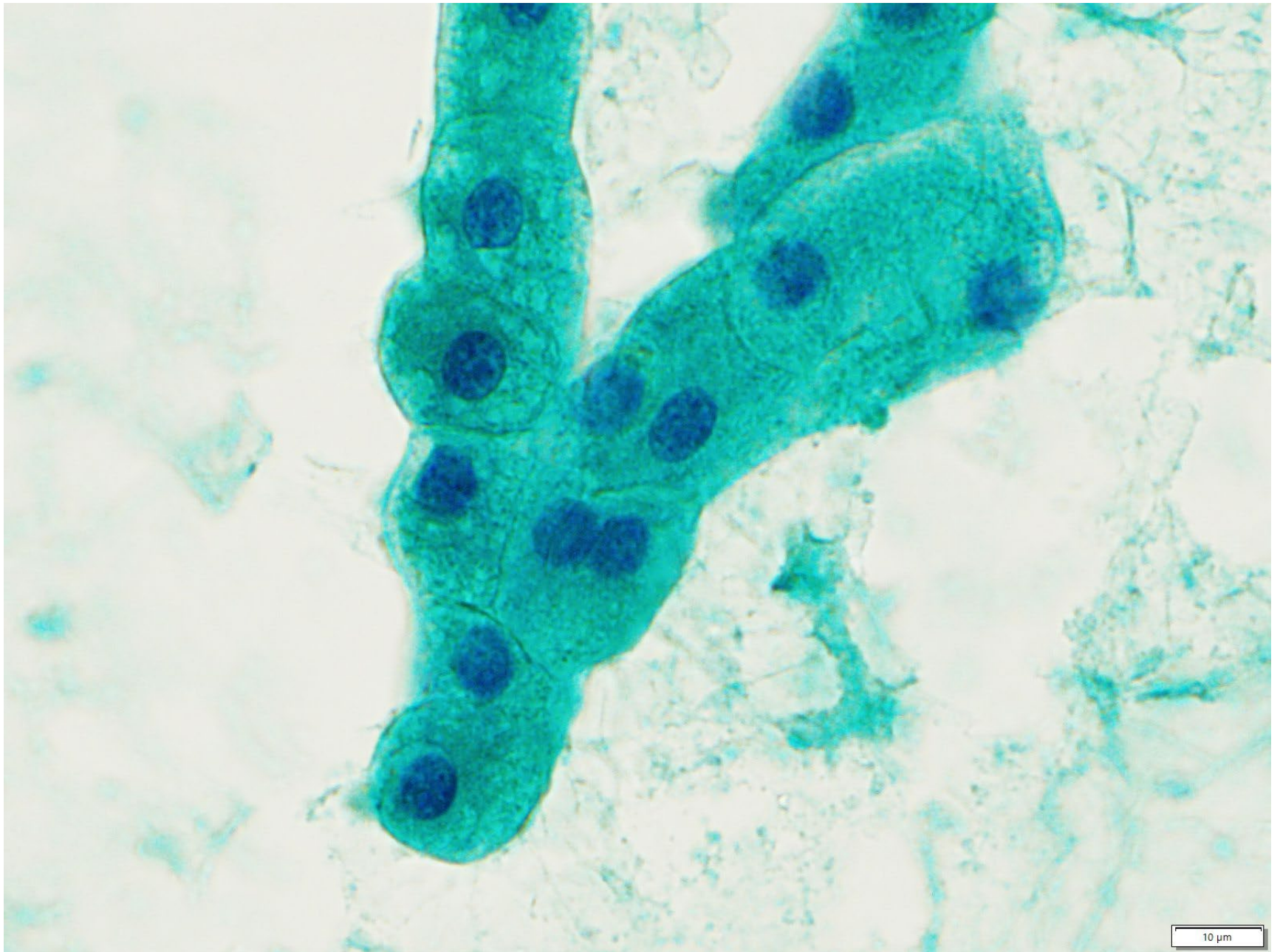


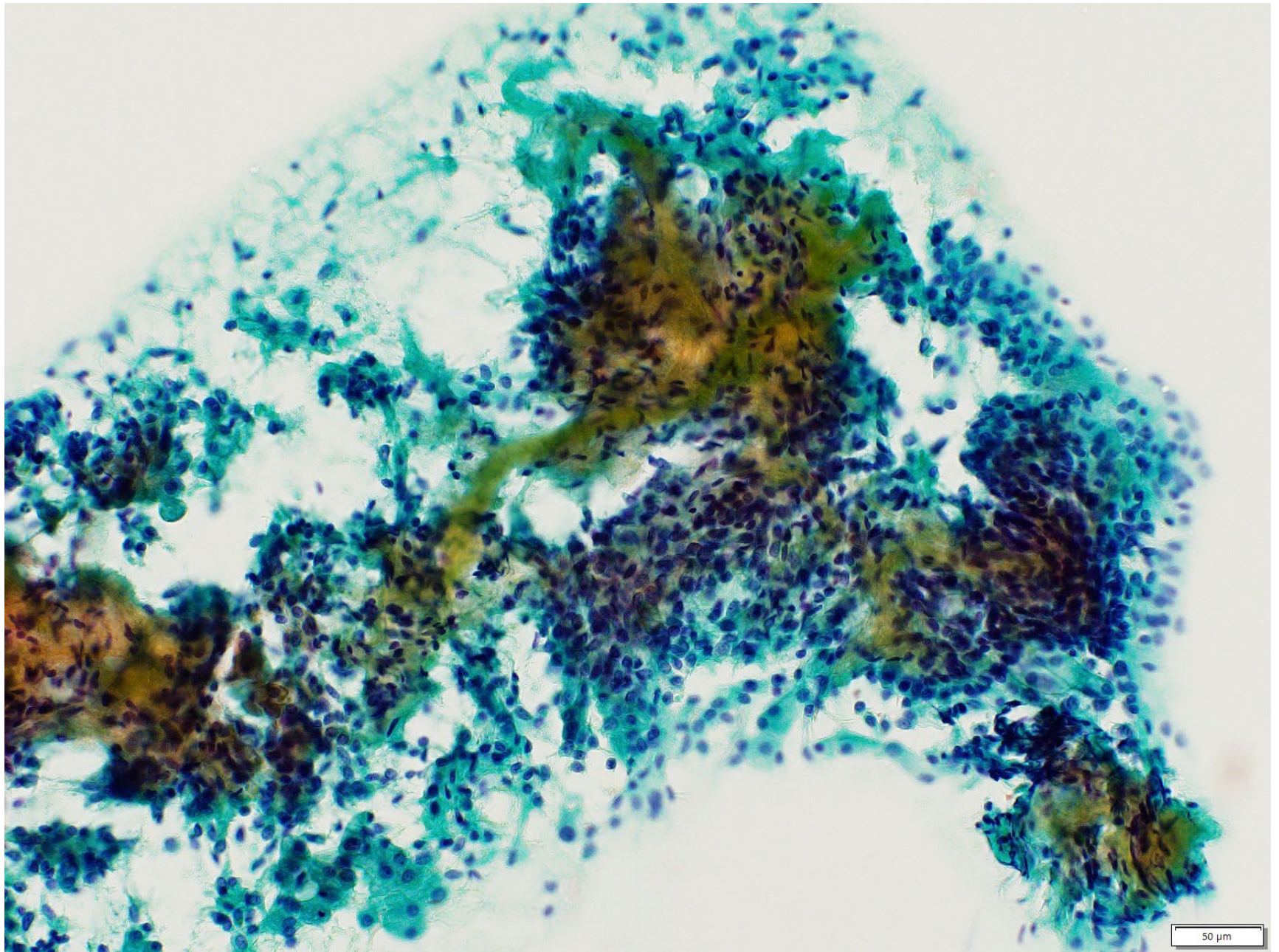


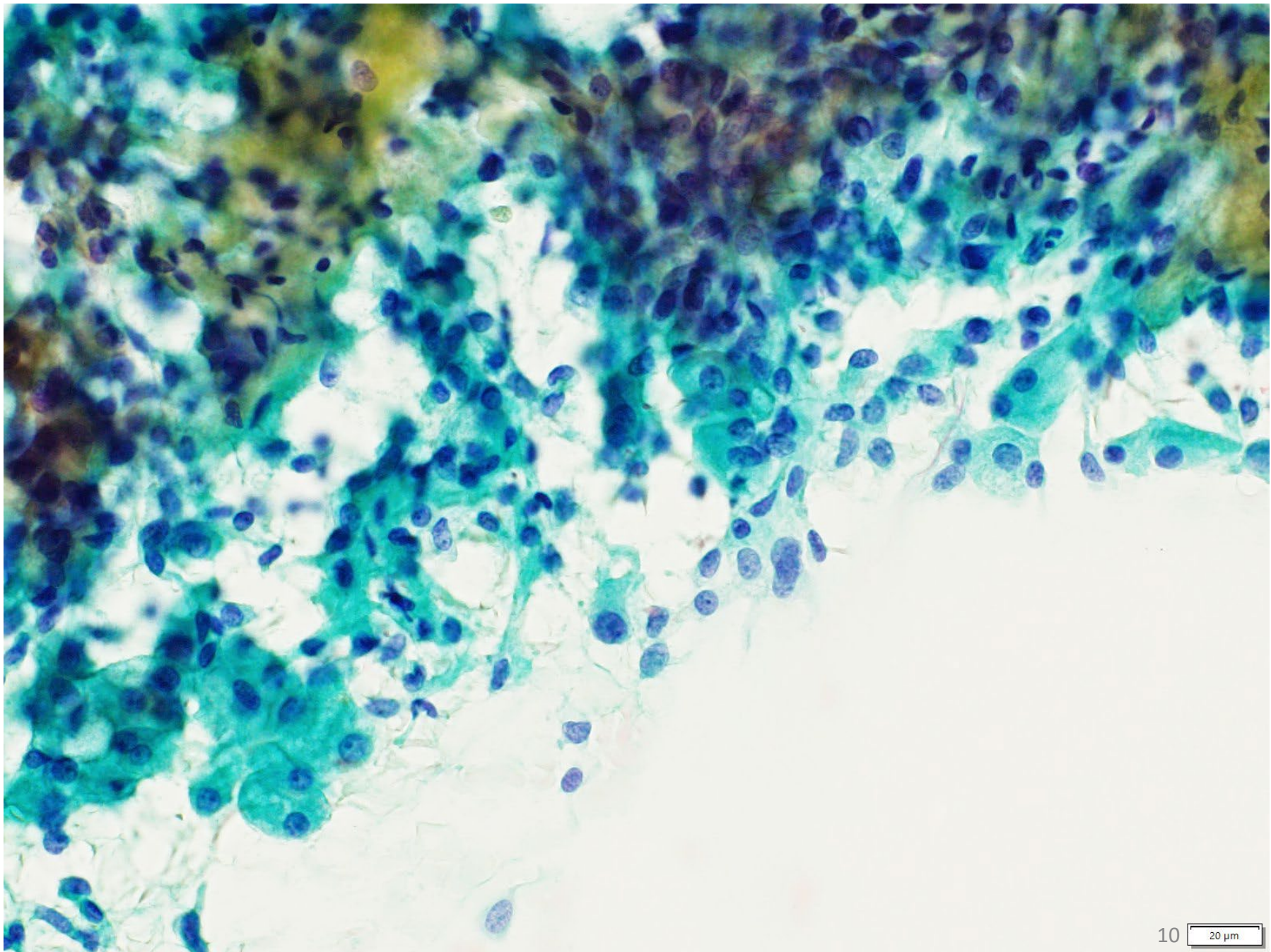
10 μ m

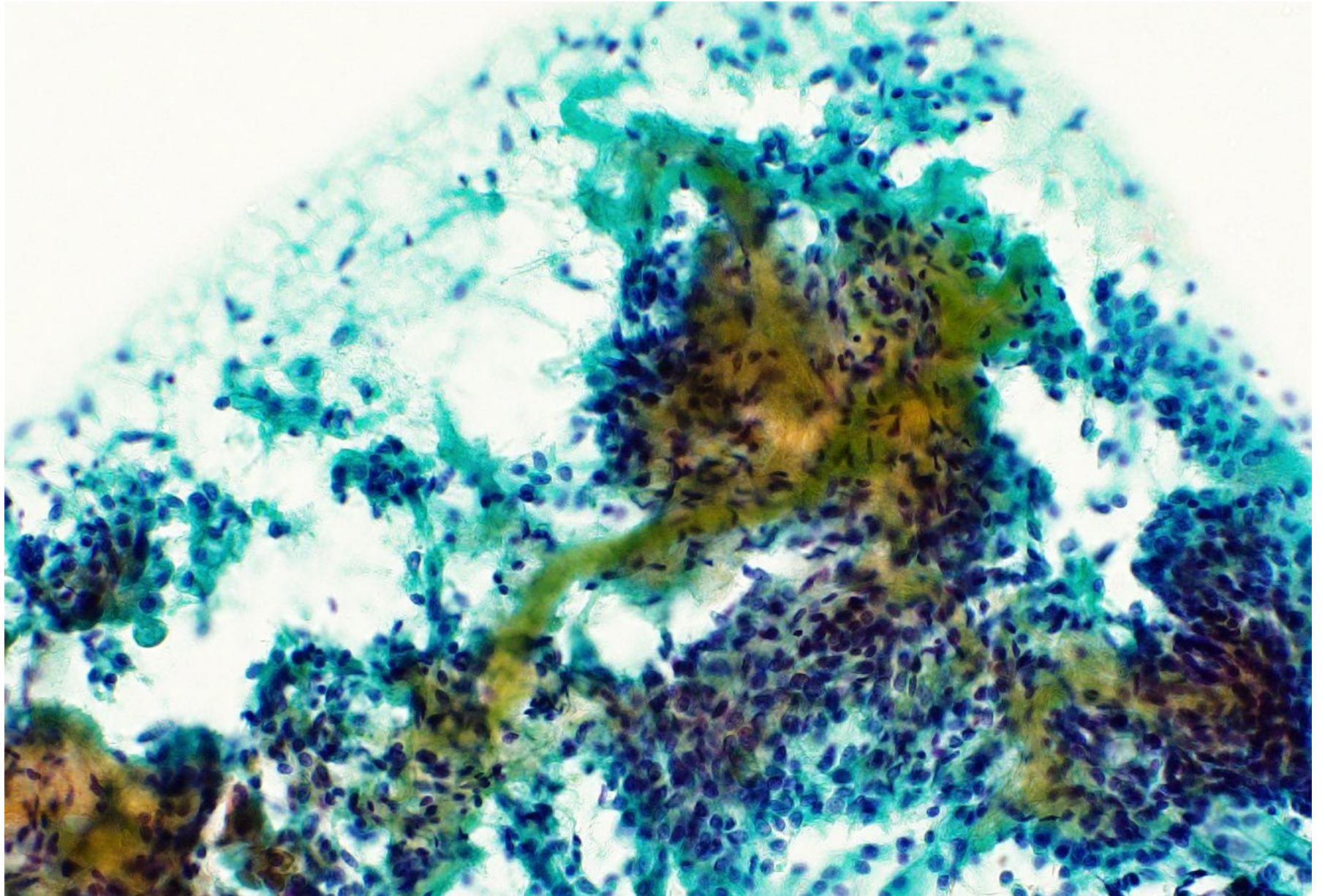




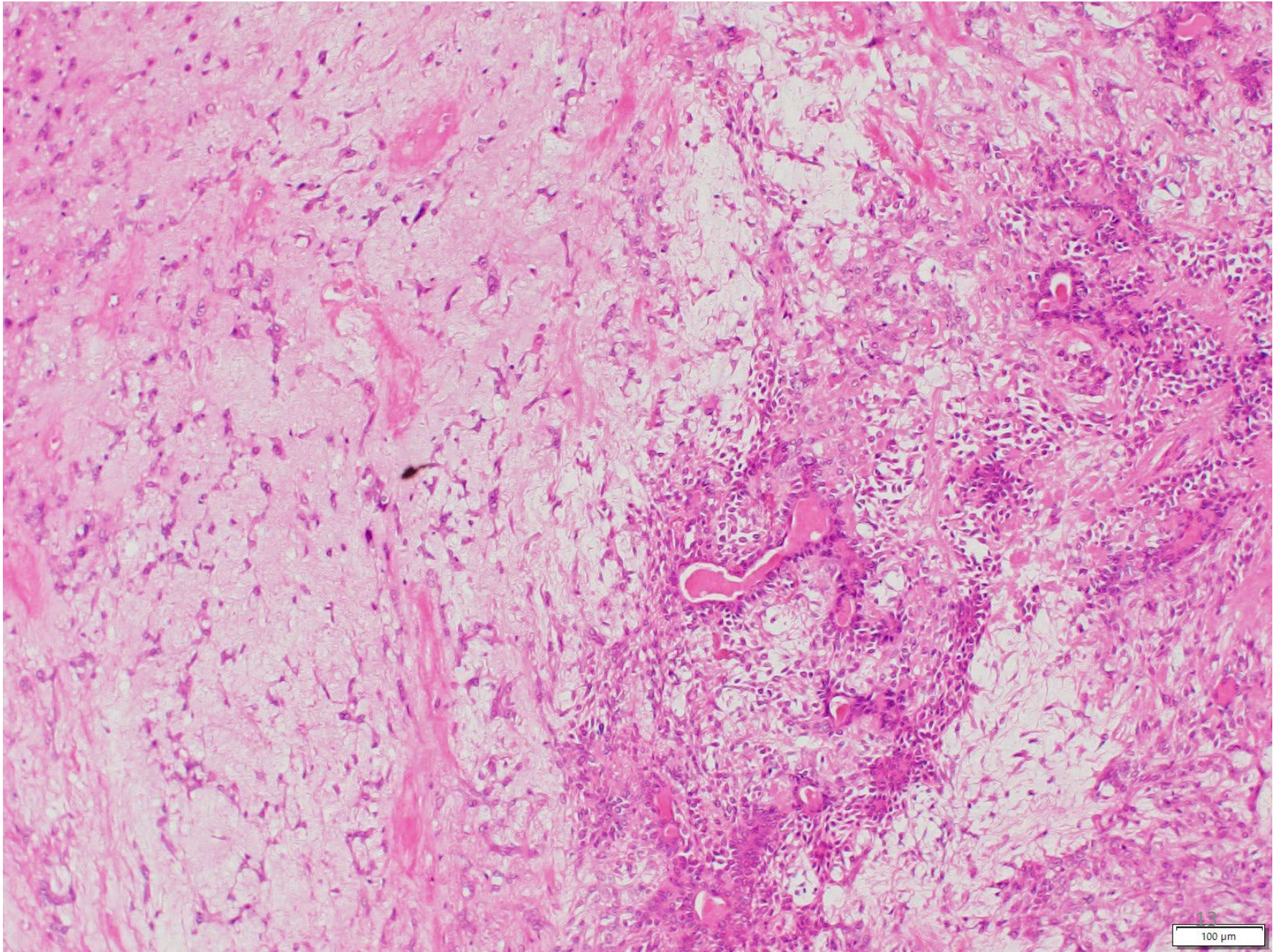


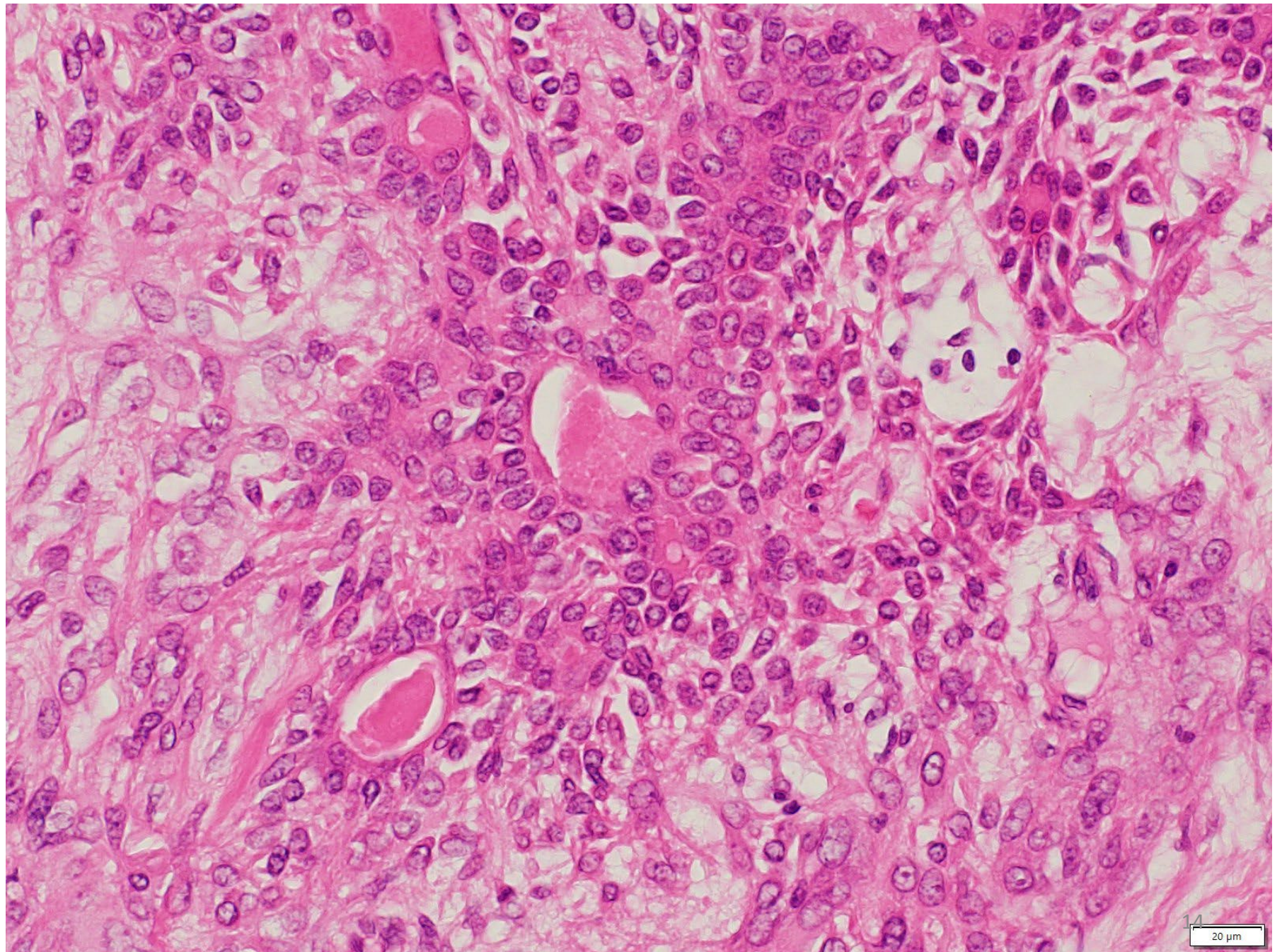


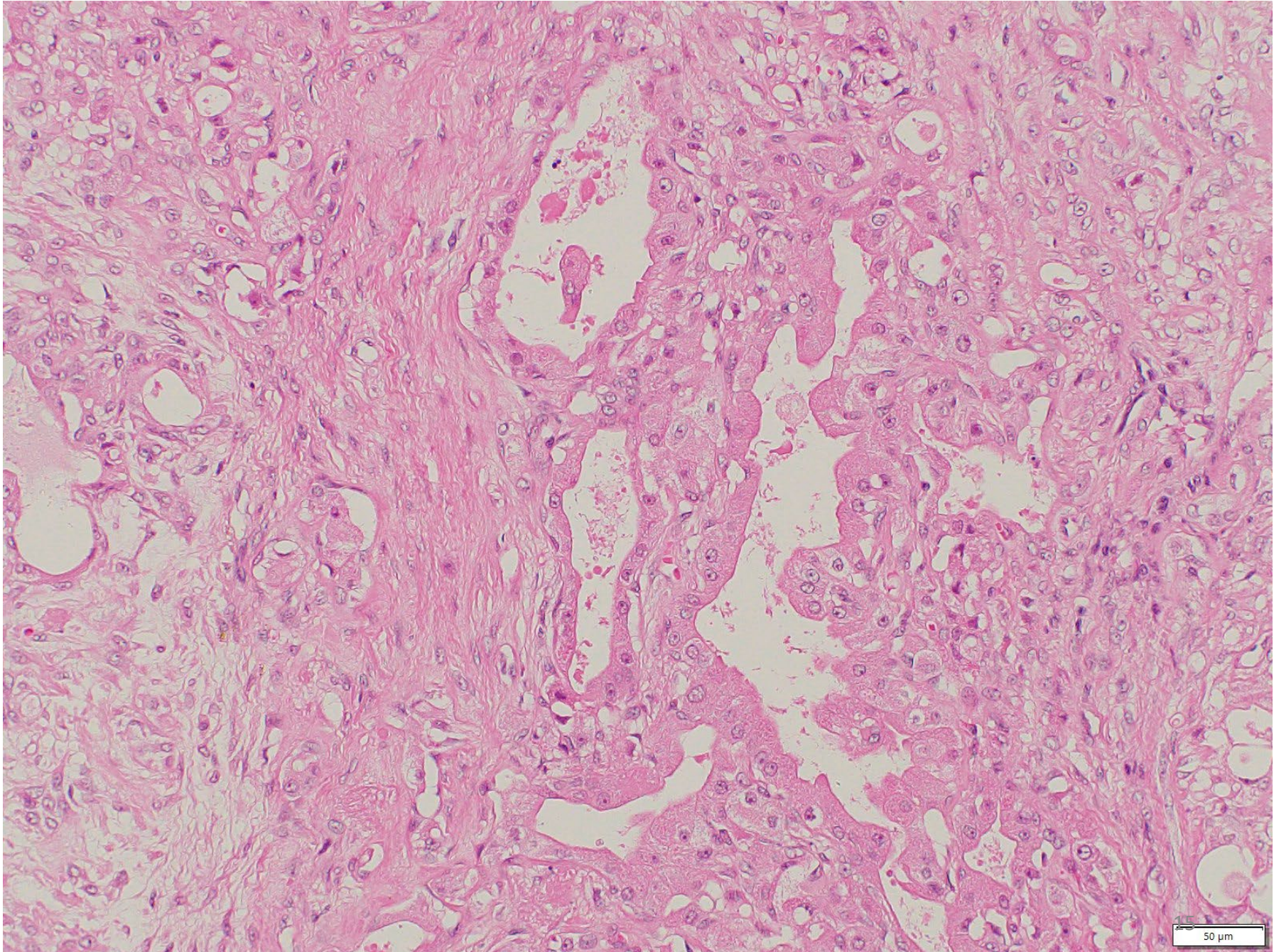


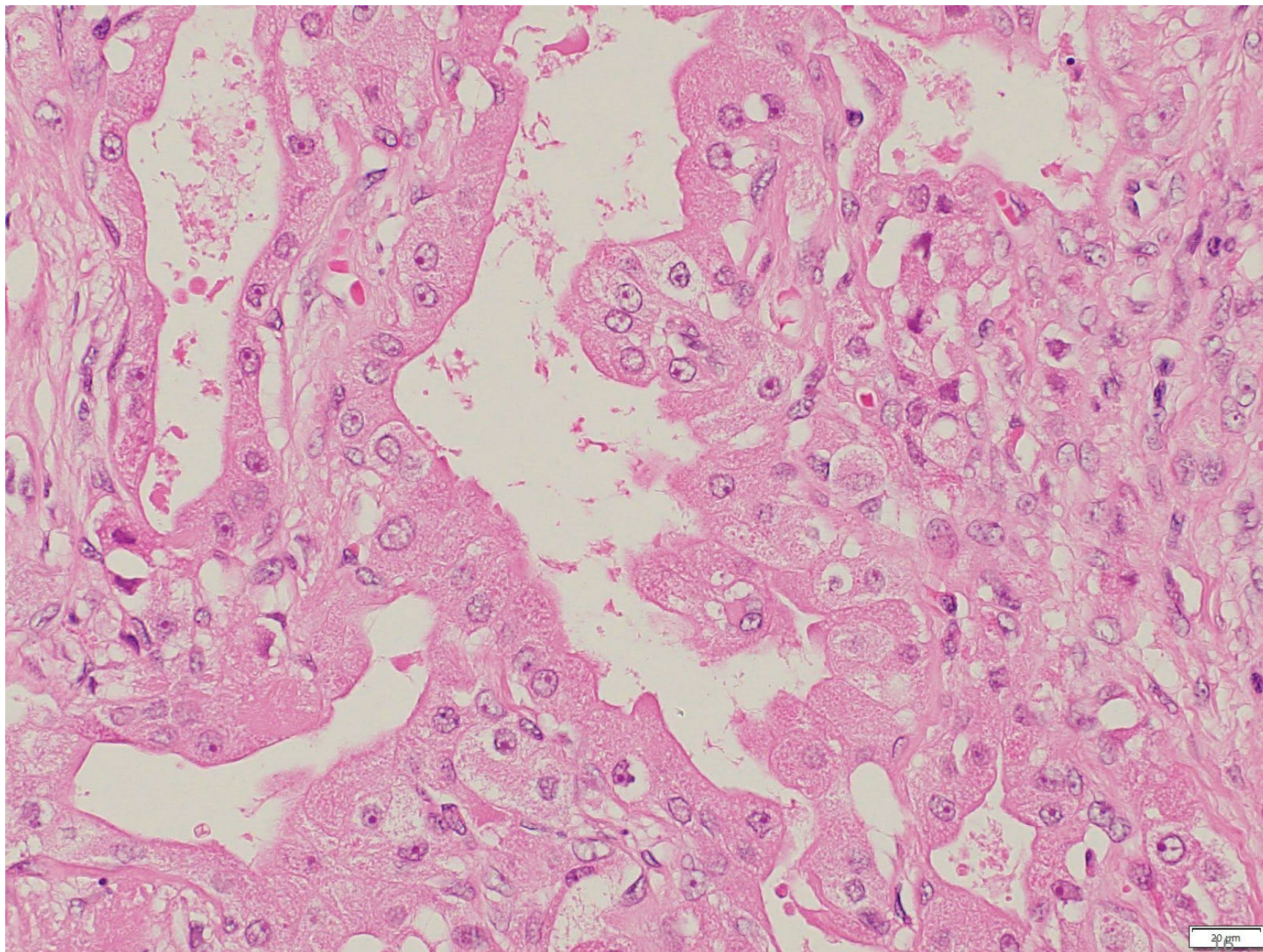


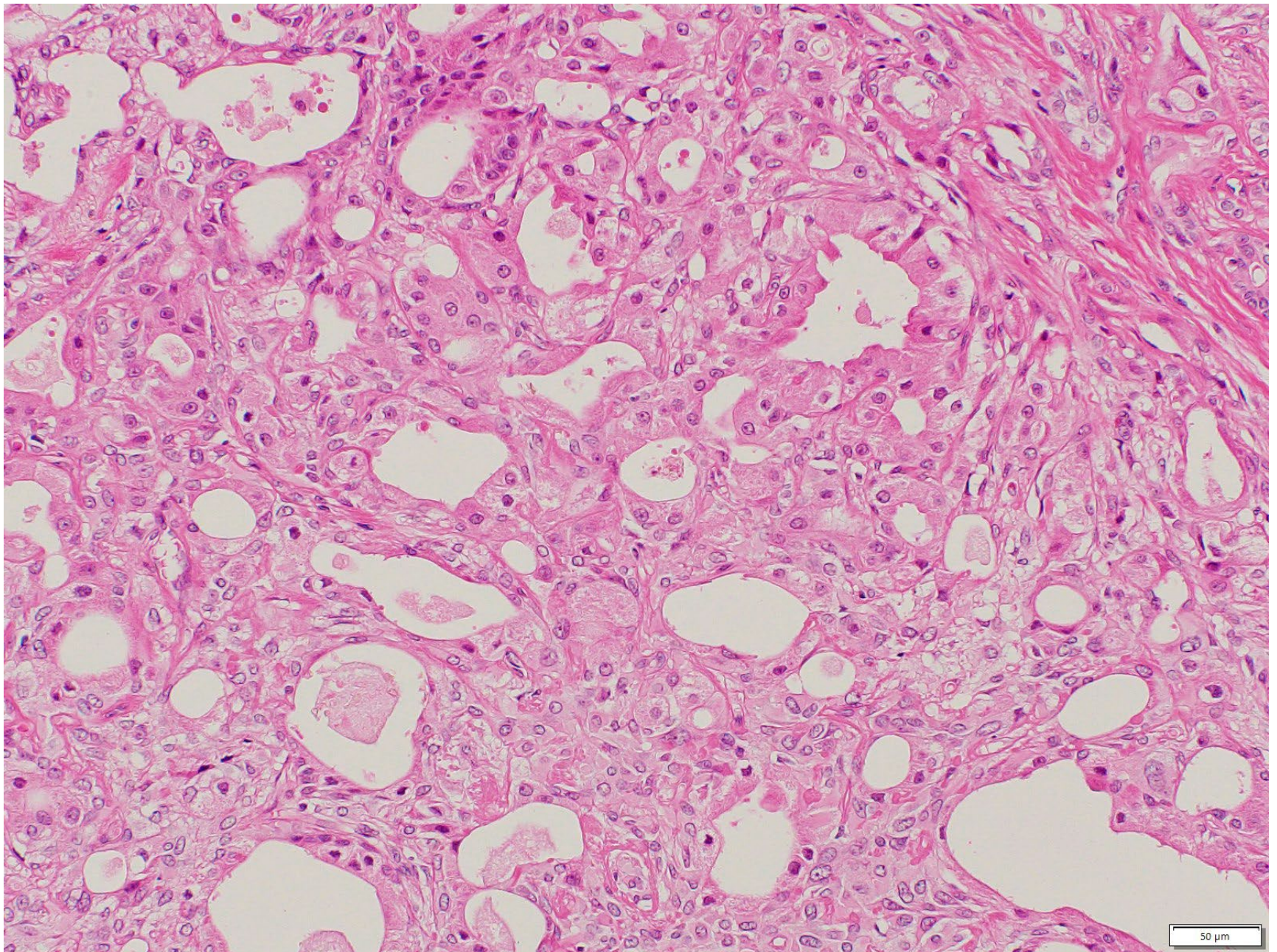
組織所見

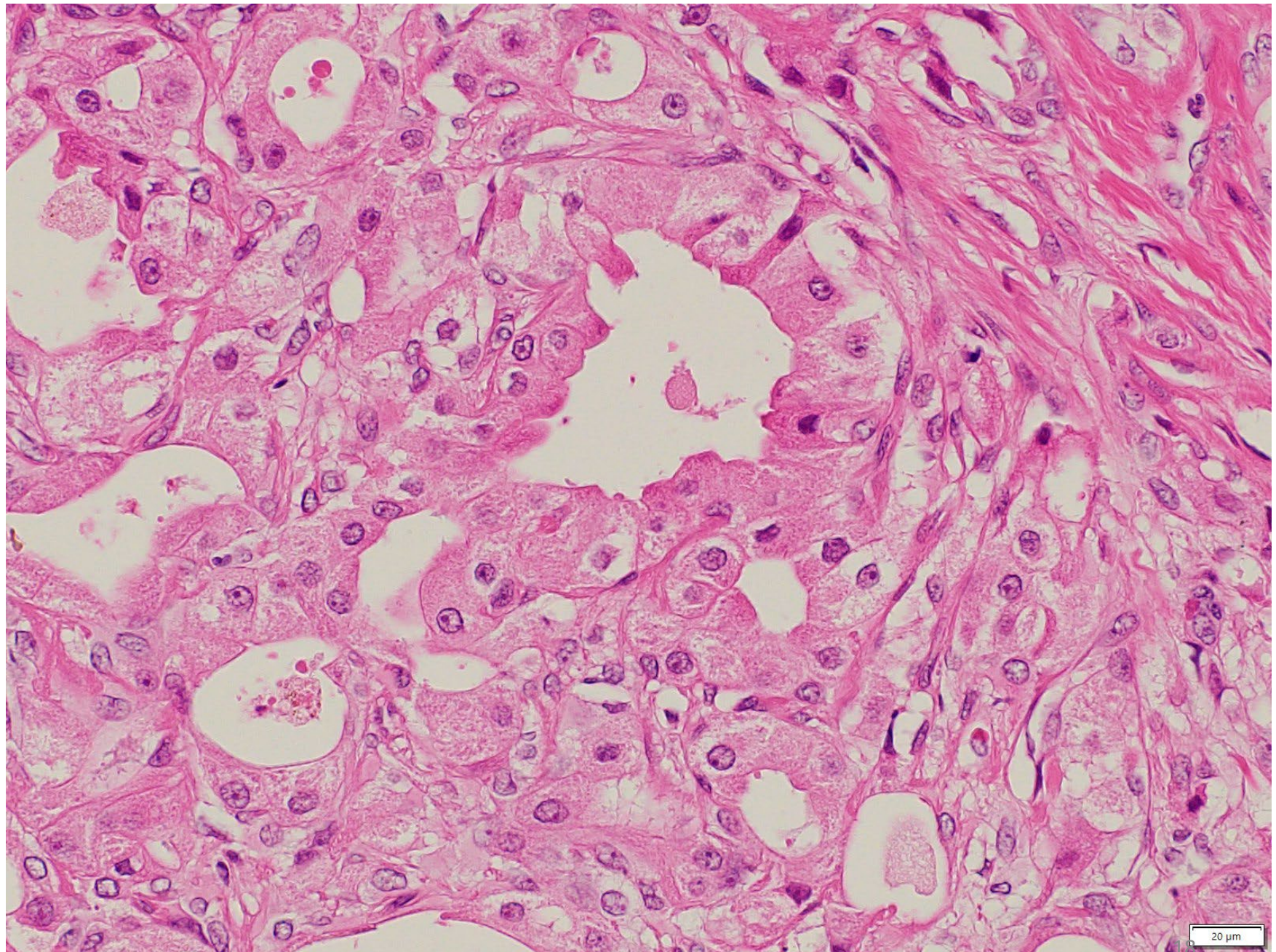






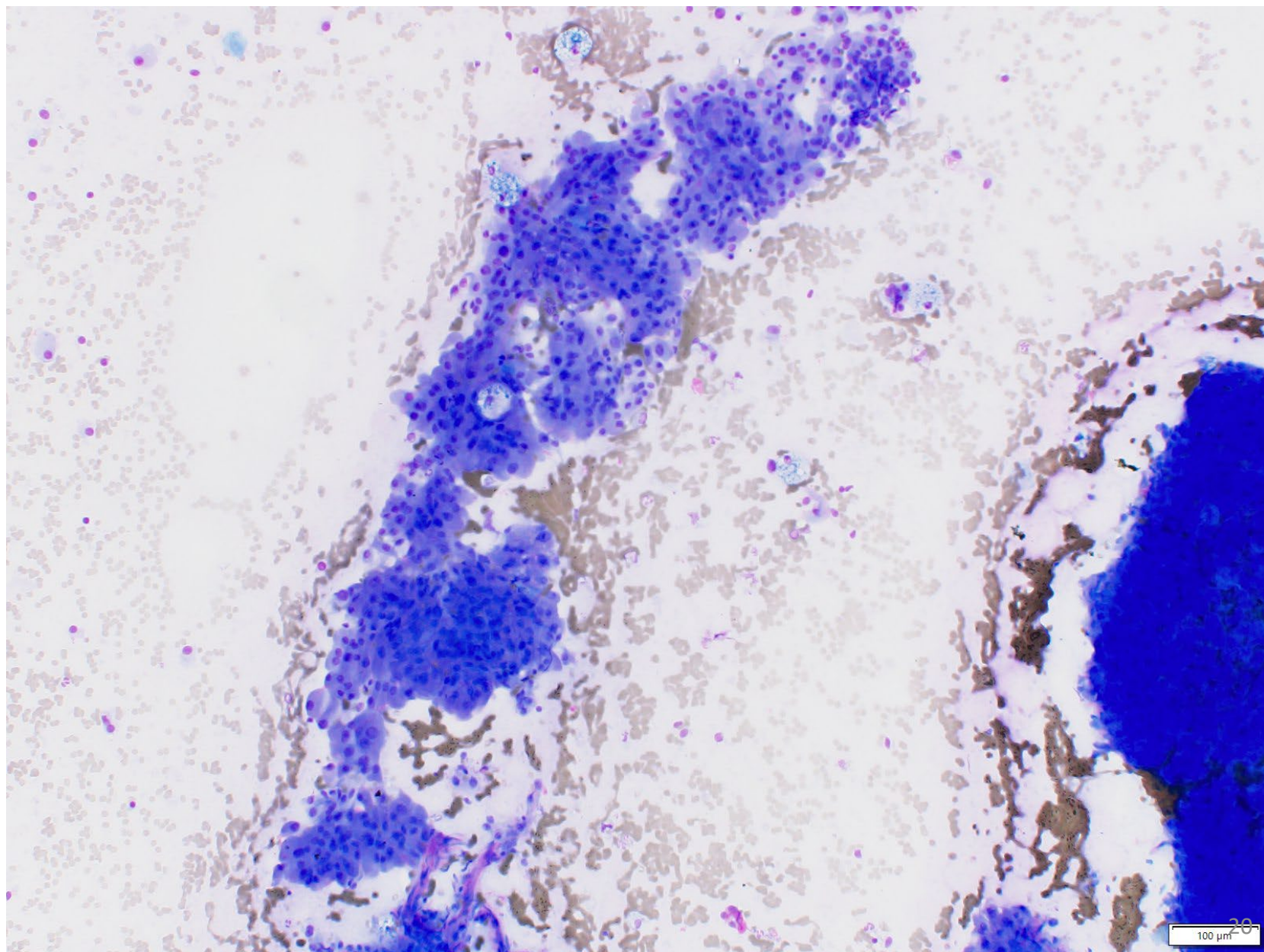


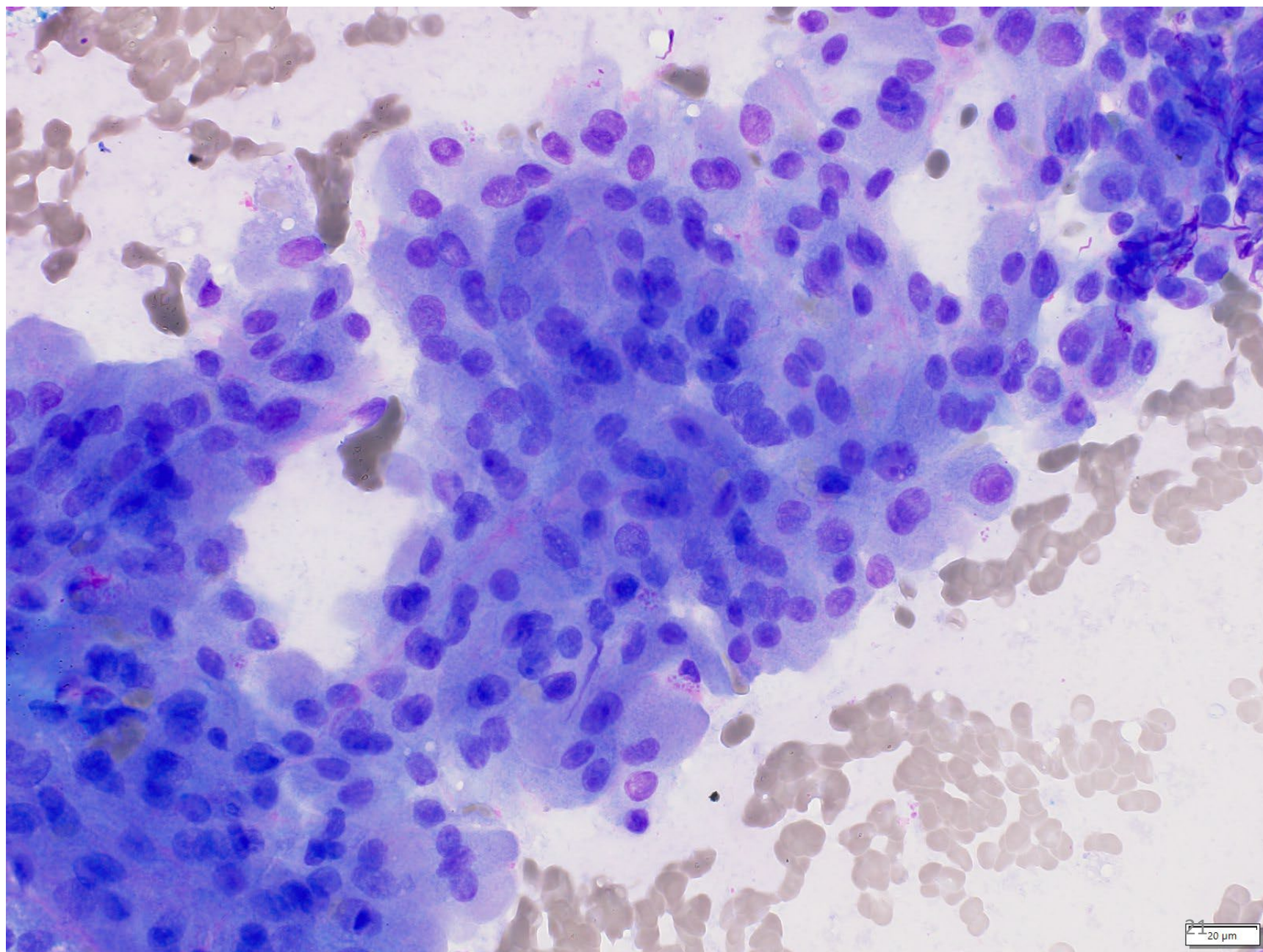


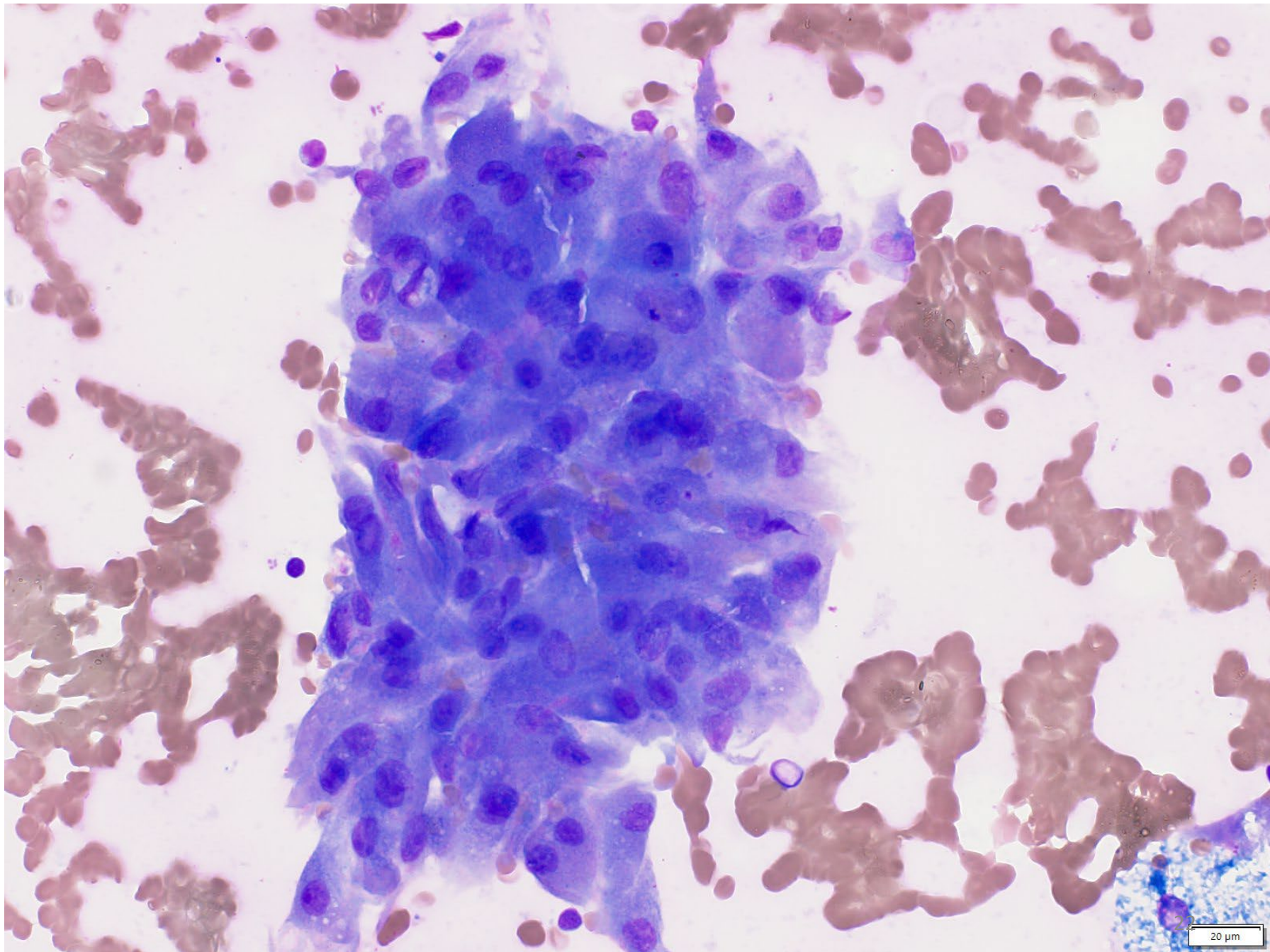


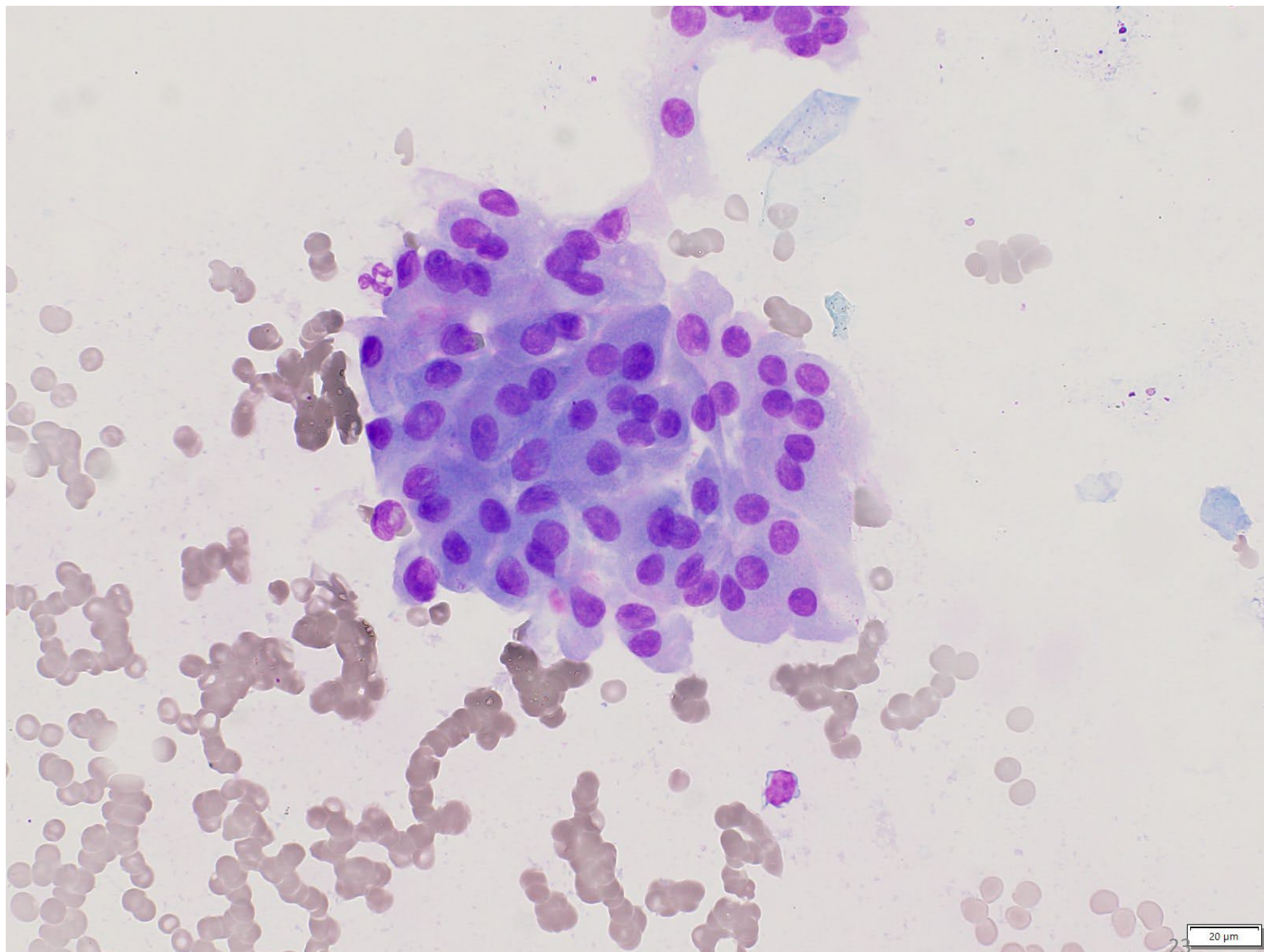
症例2

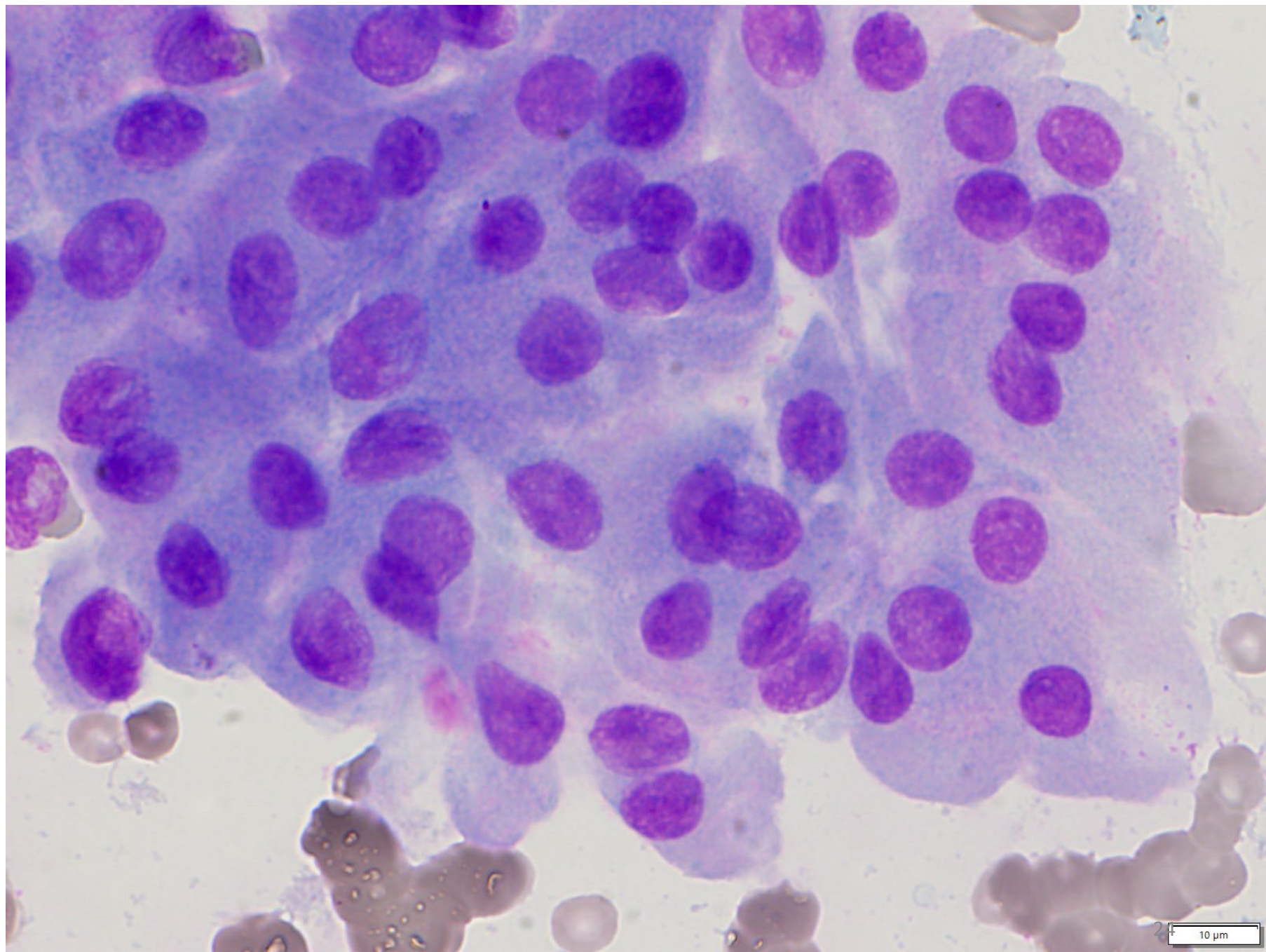
44歳、女性、右耳下腺穿刺

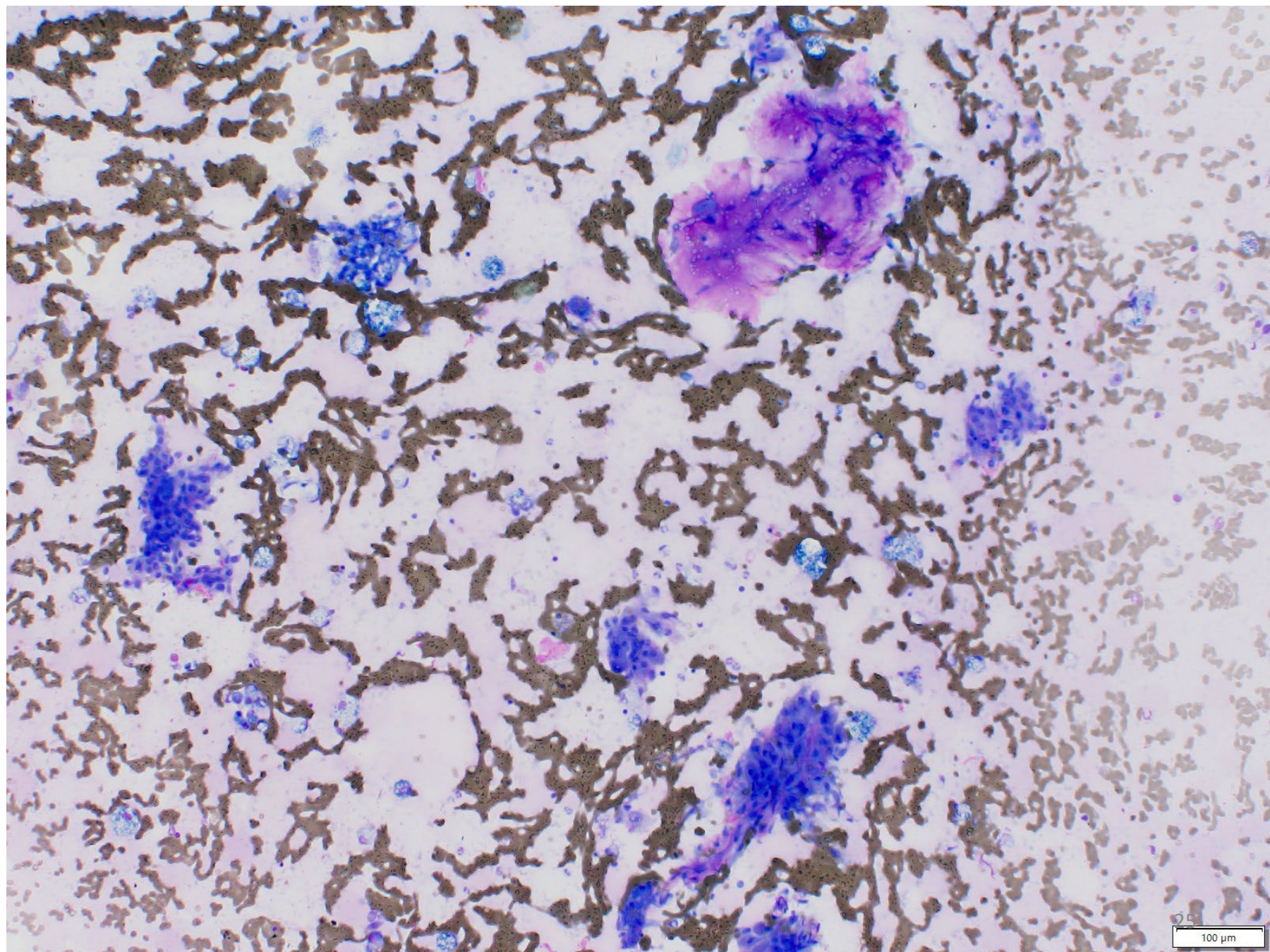


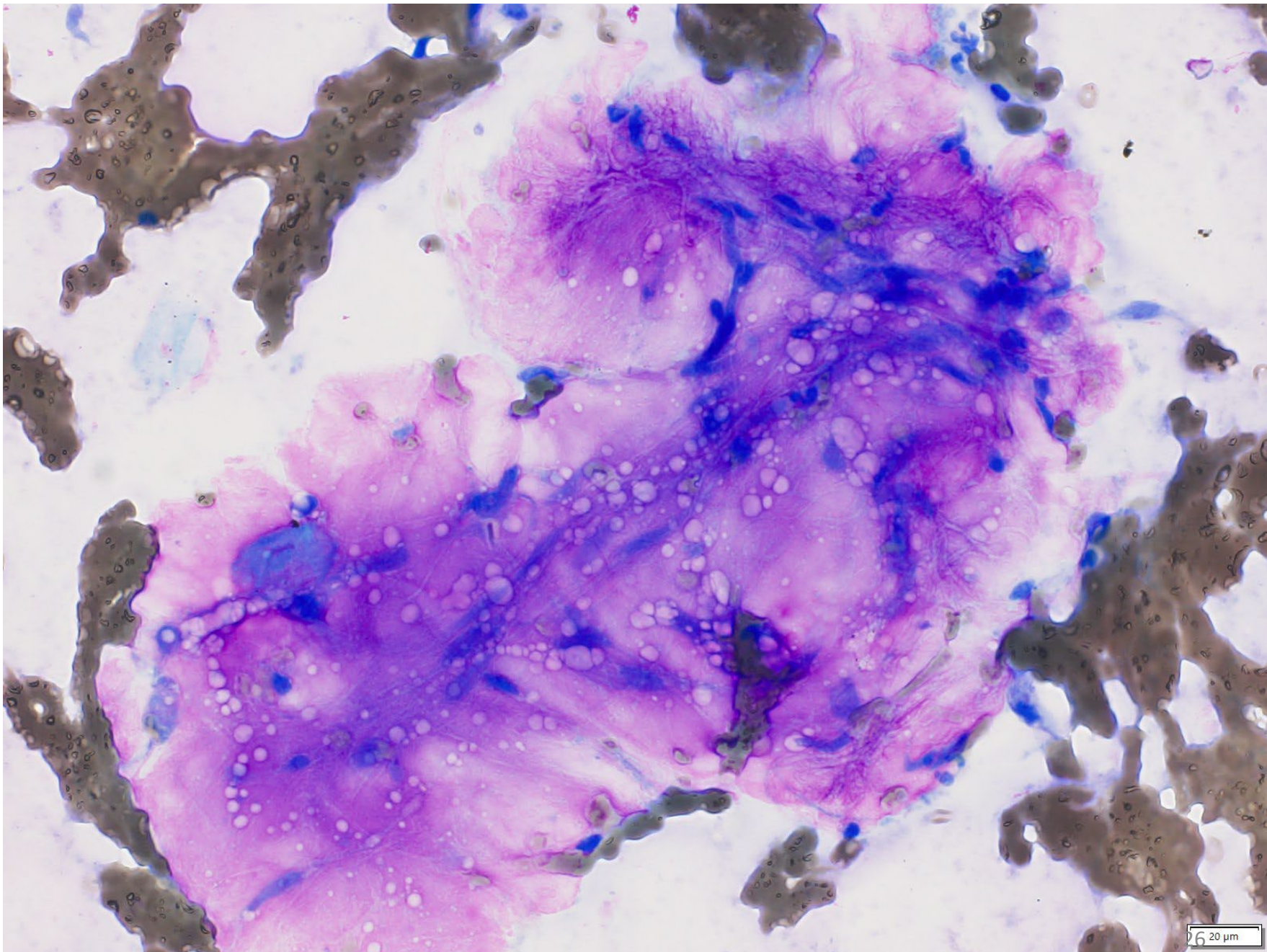


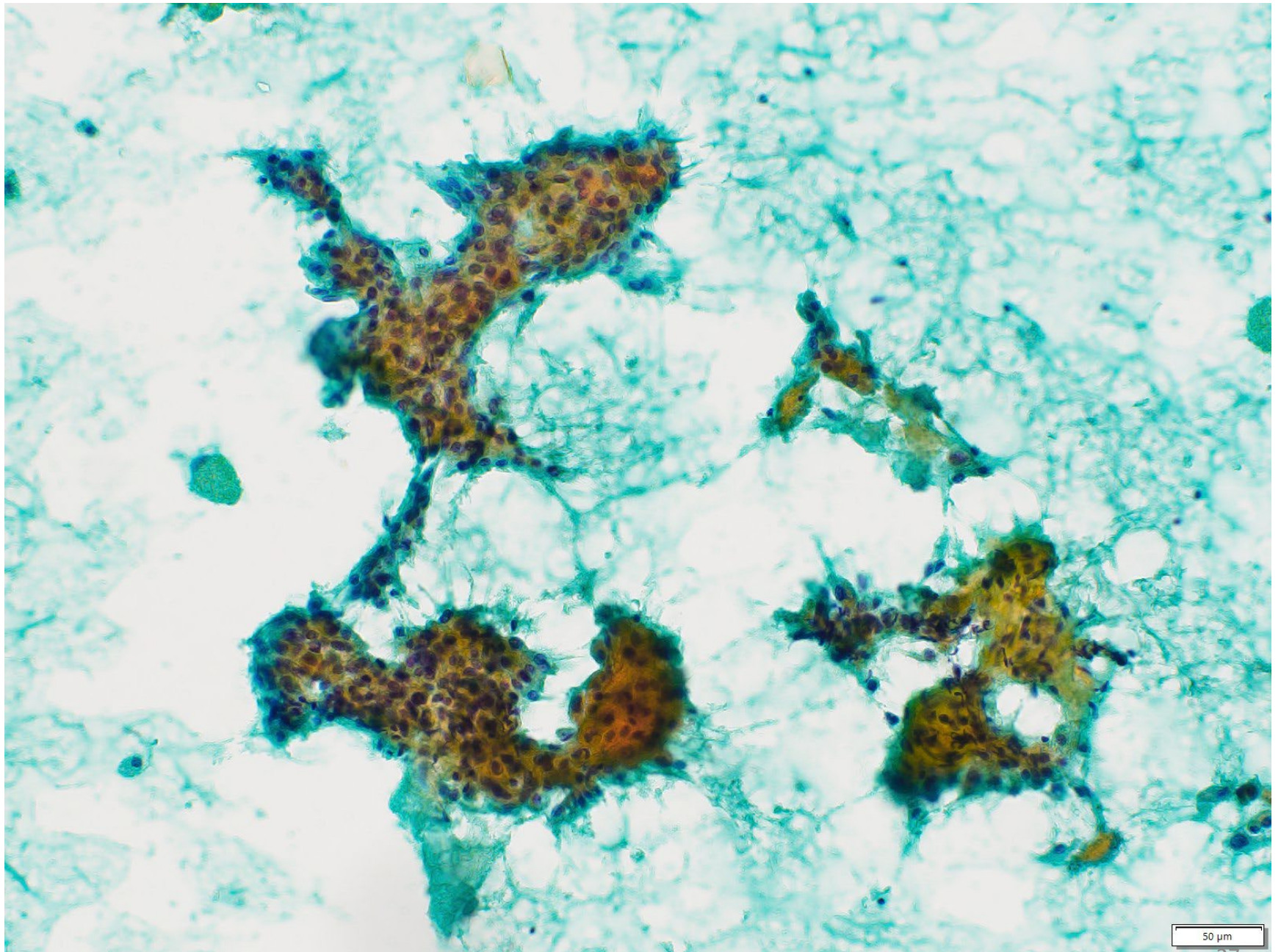




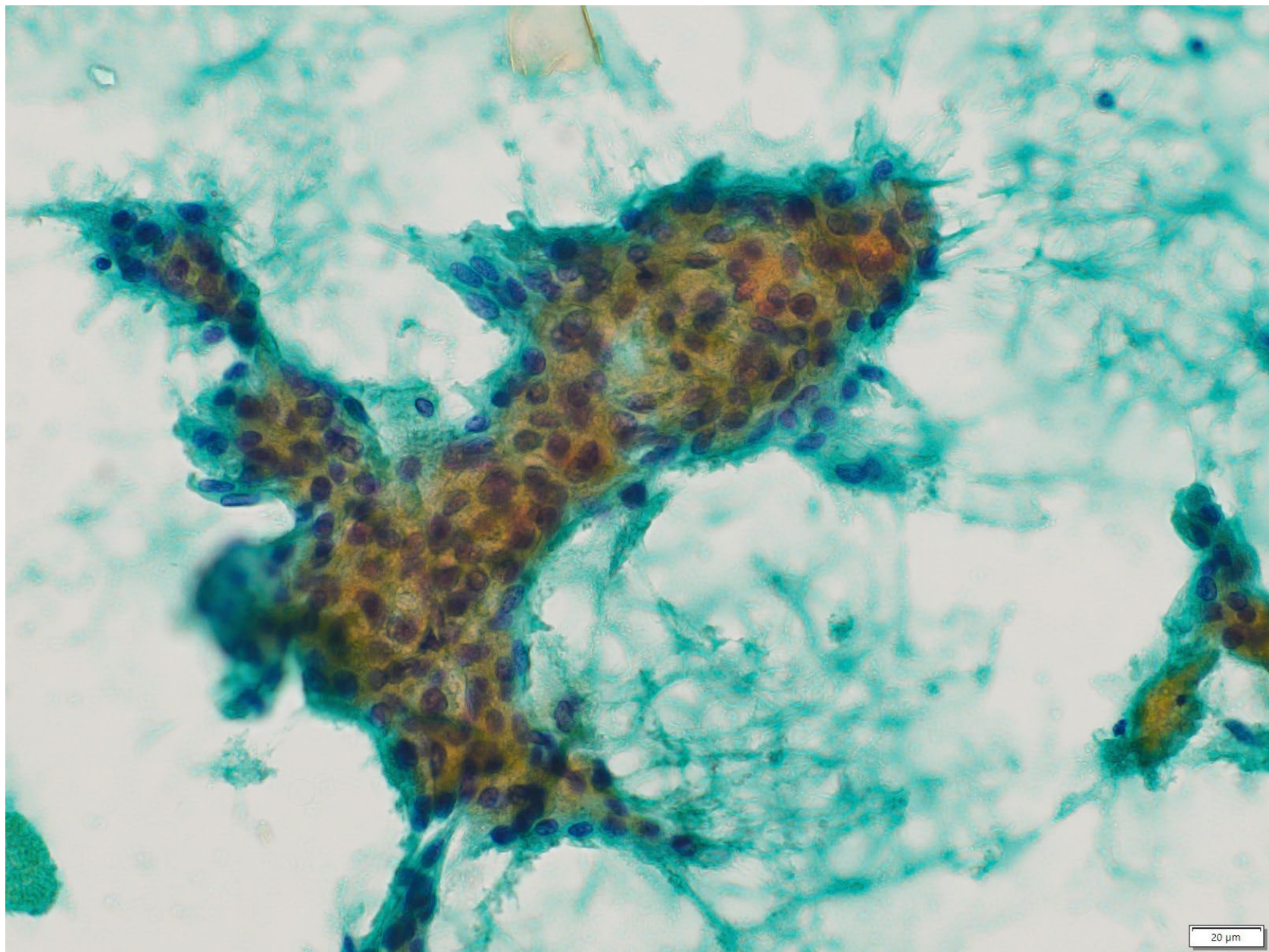




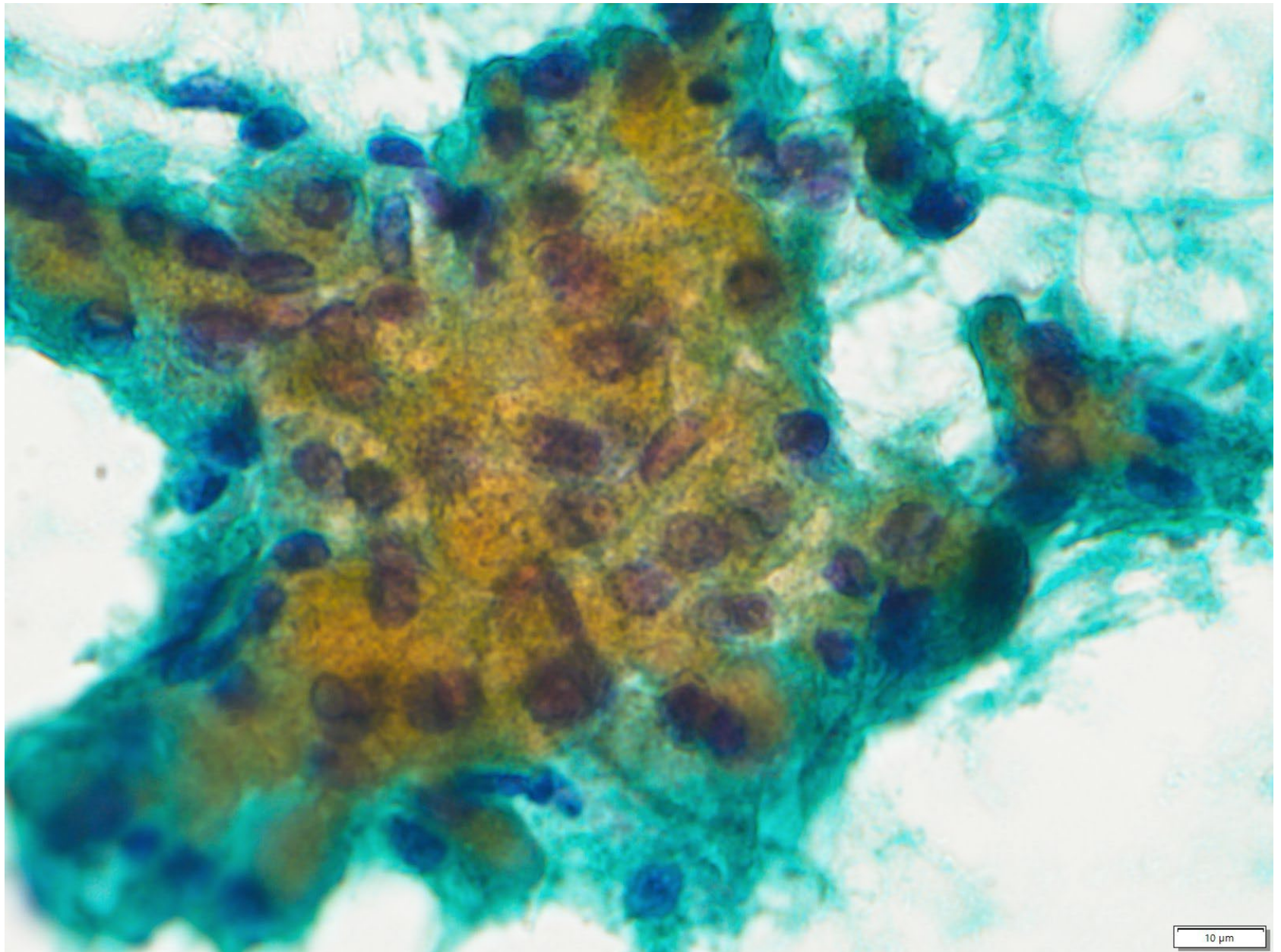


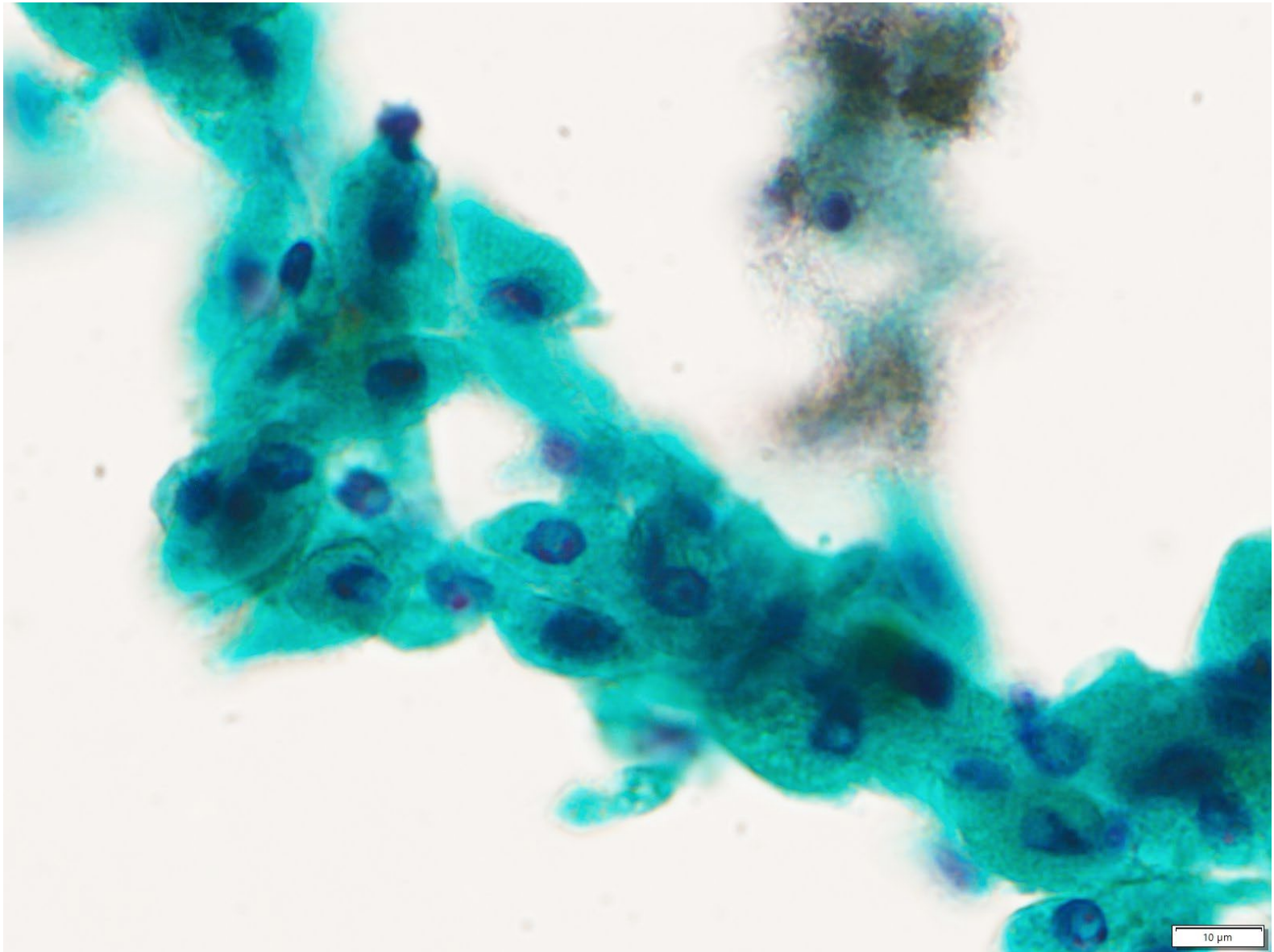


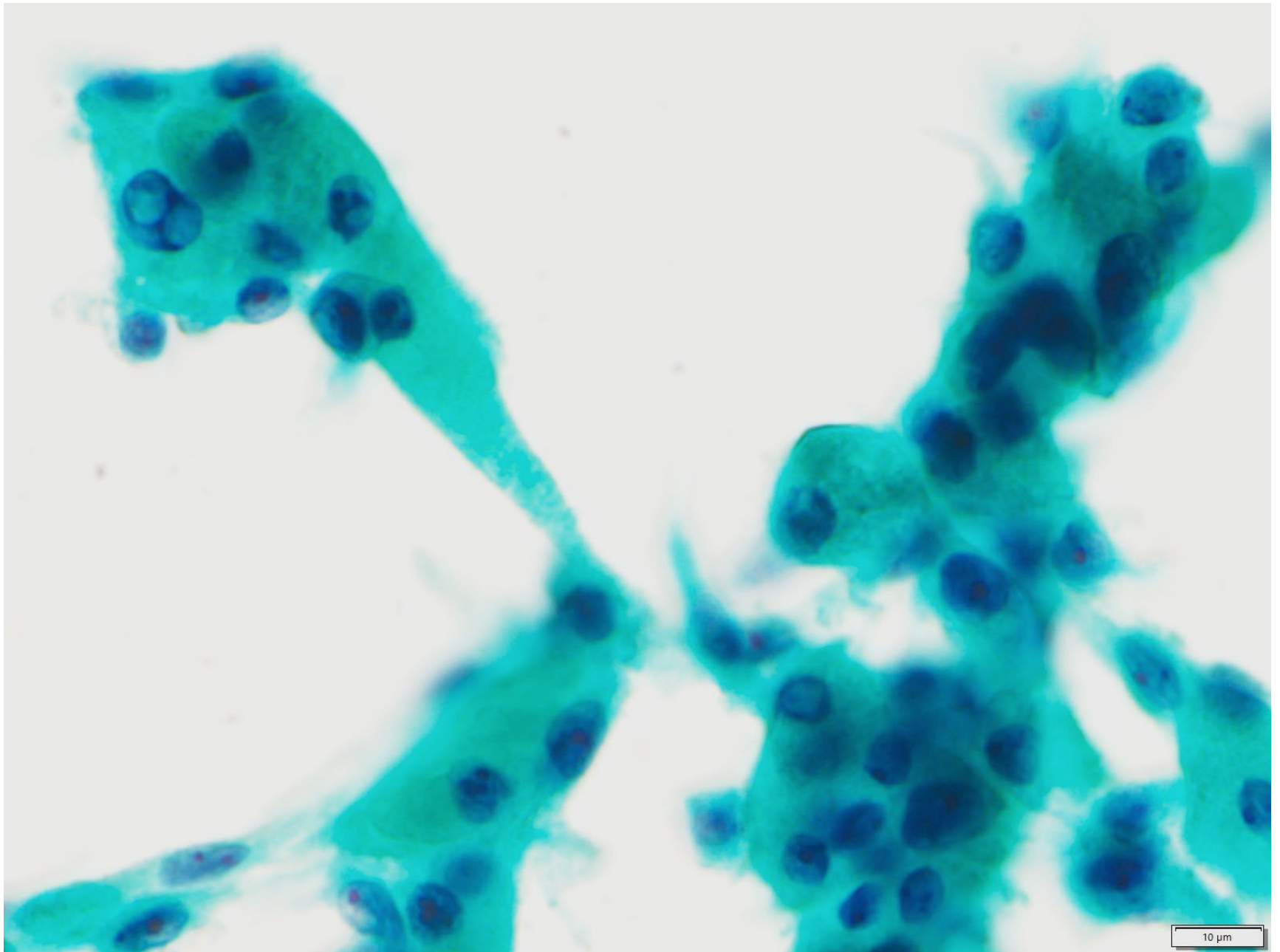
50 μ m



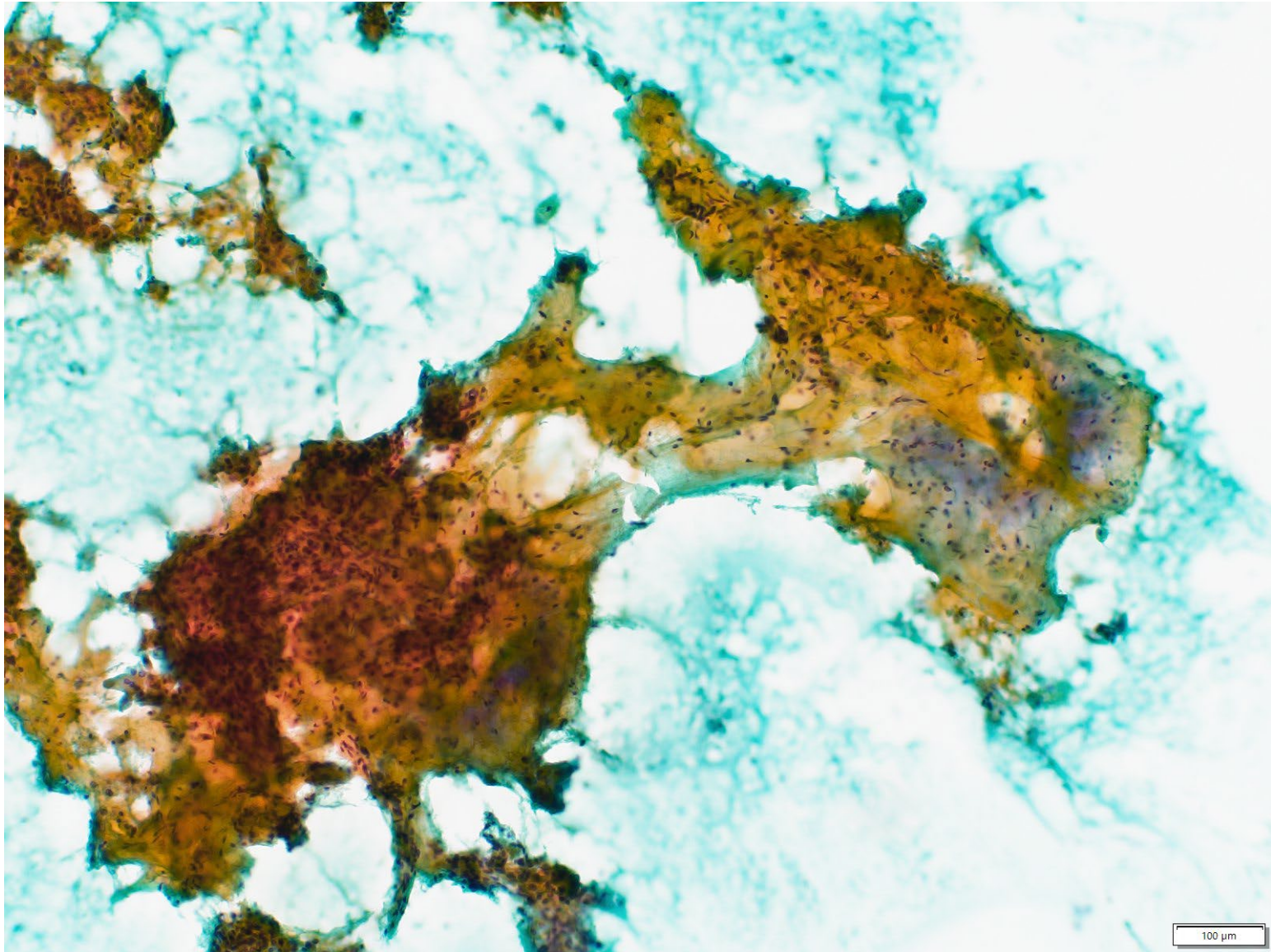
20 μm

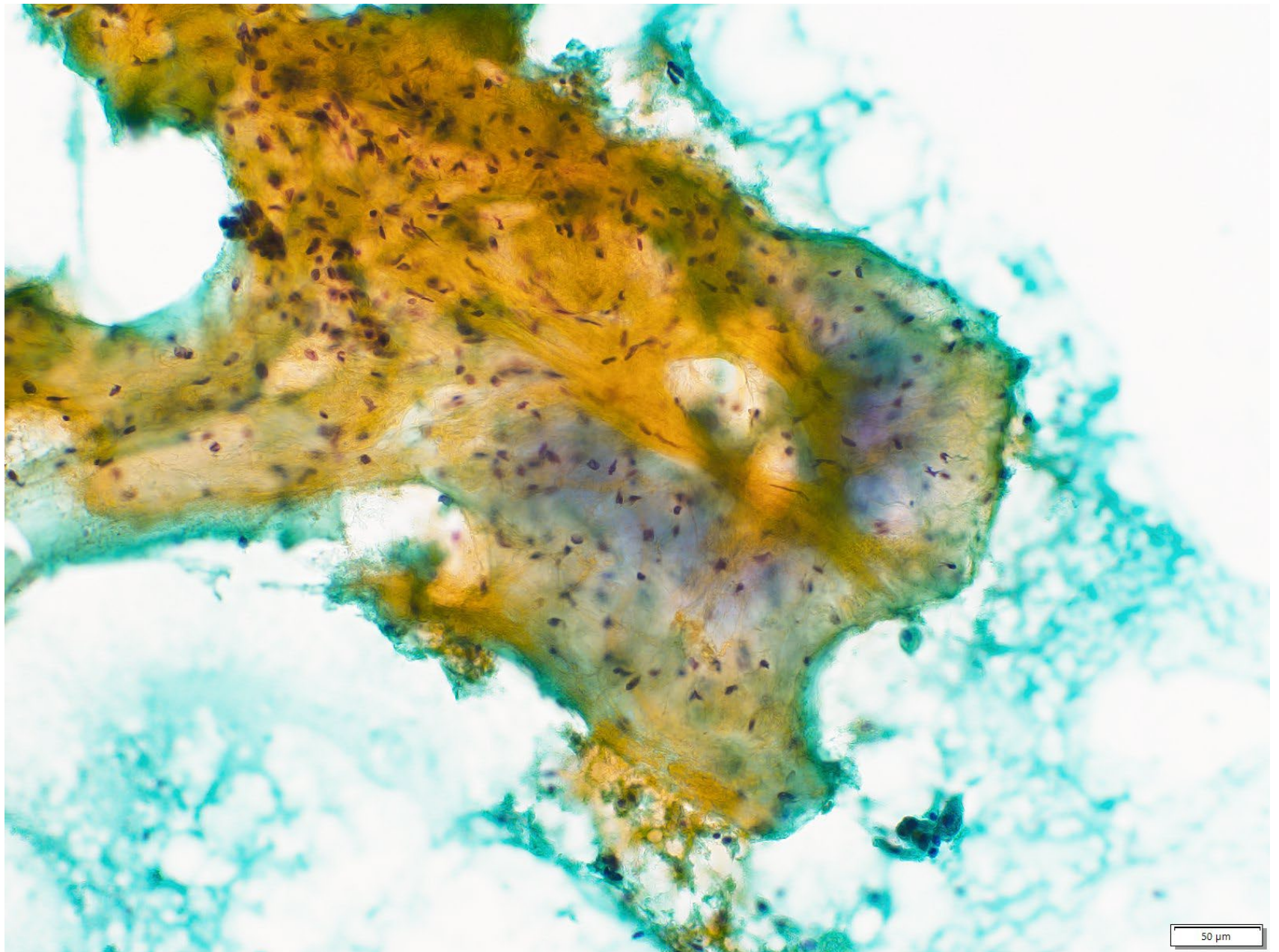






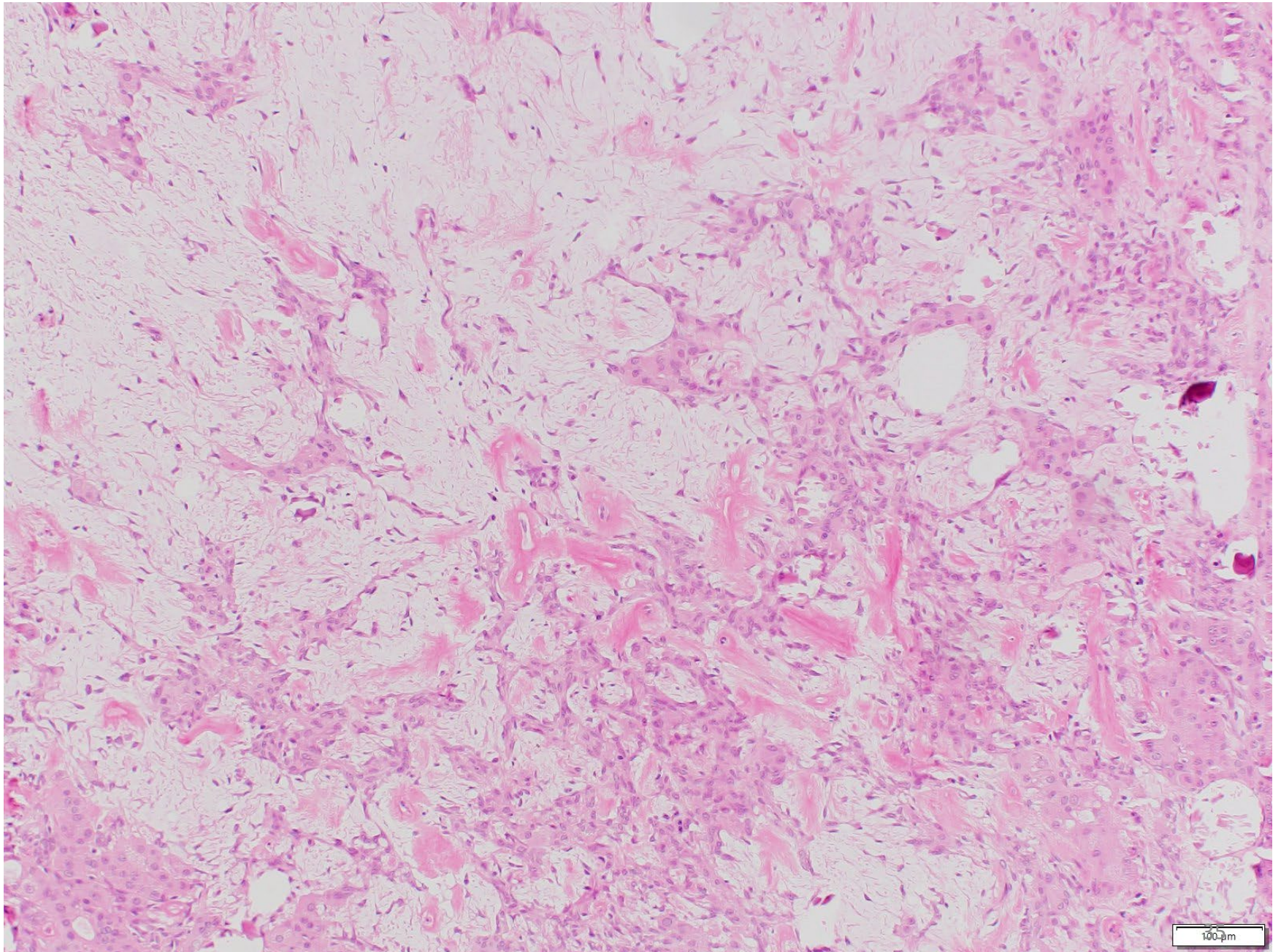
10 μm

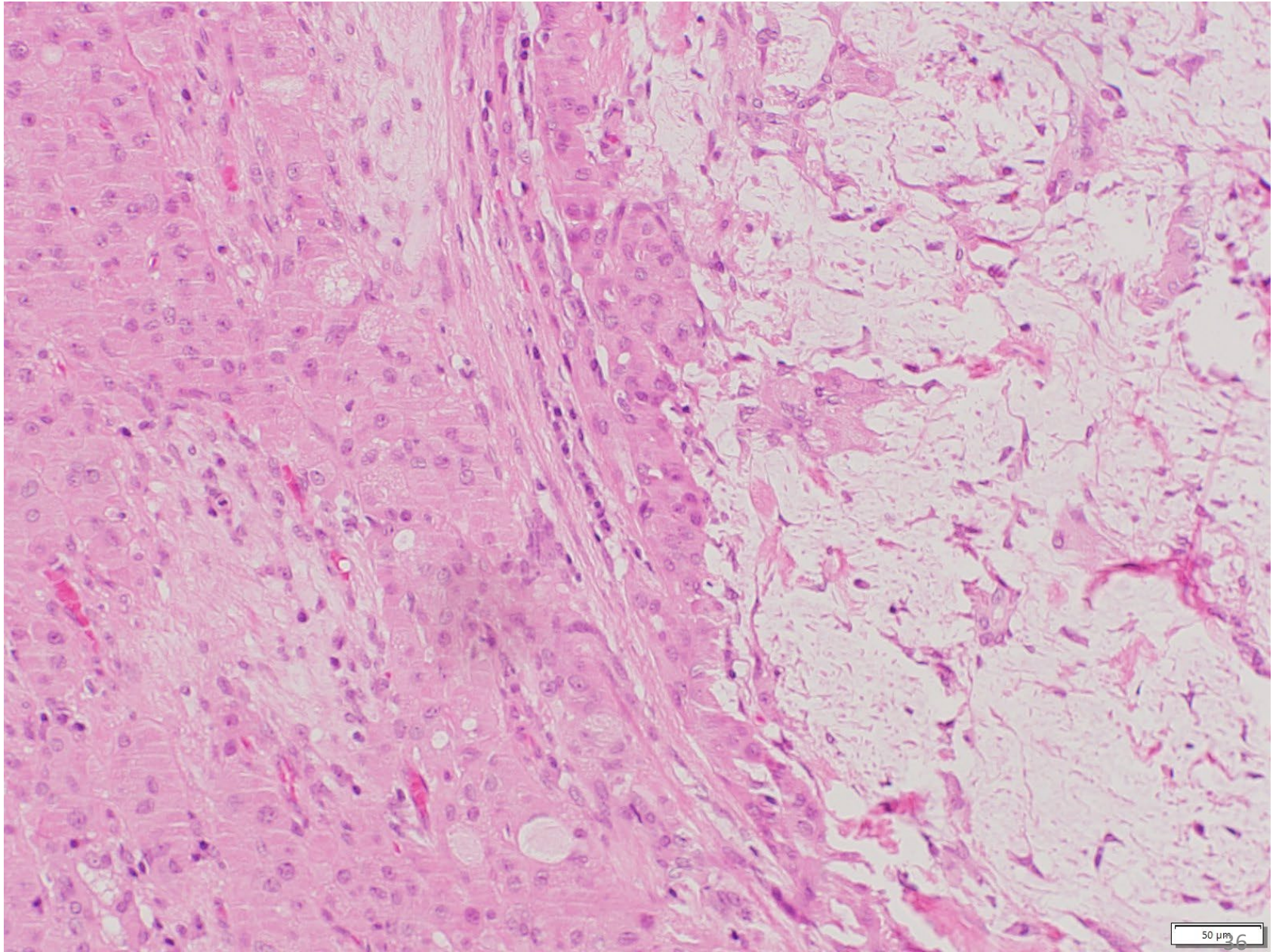


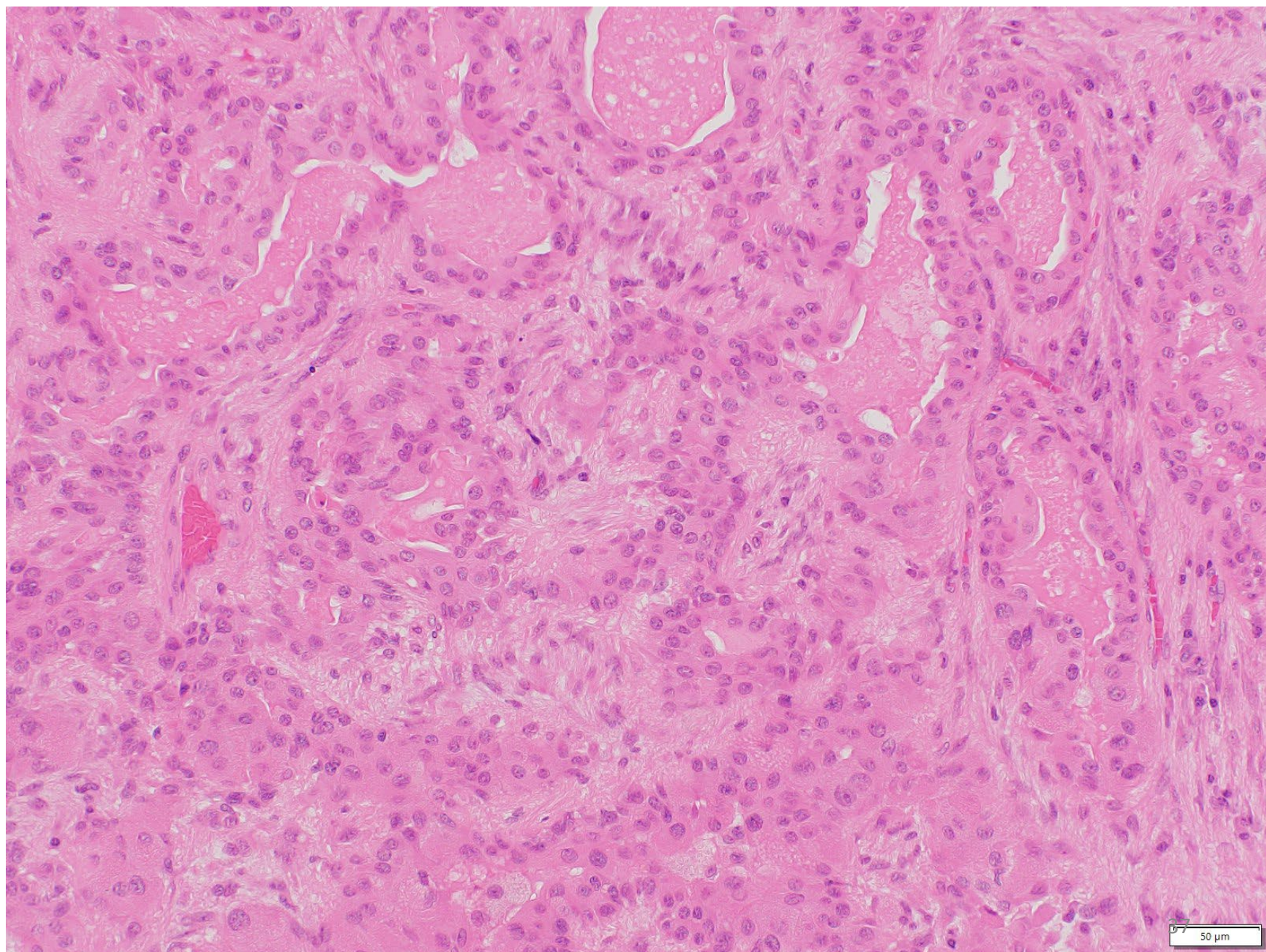


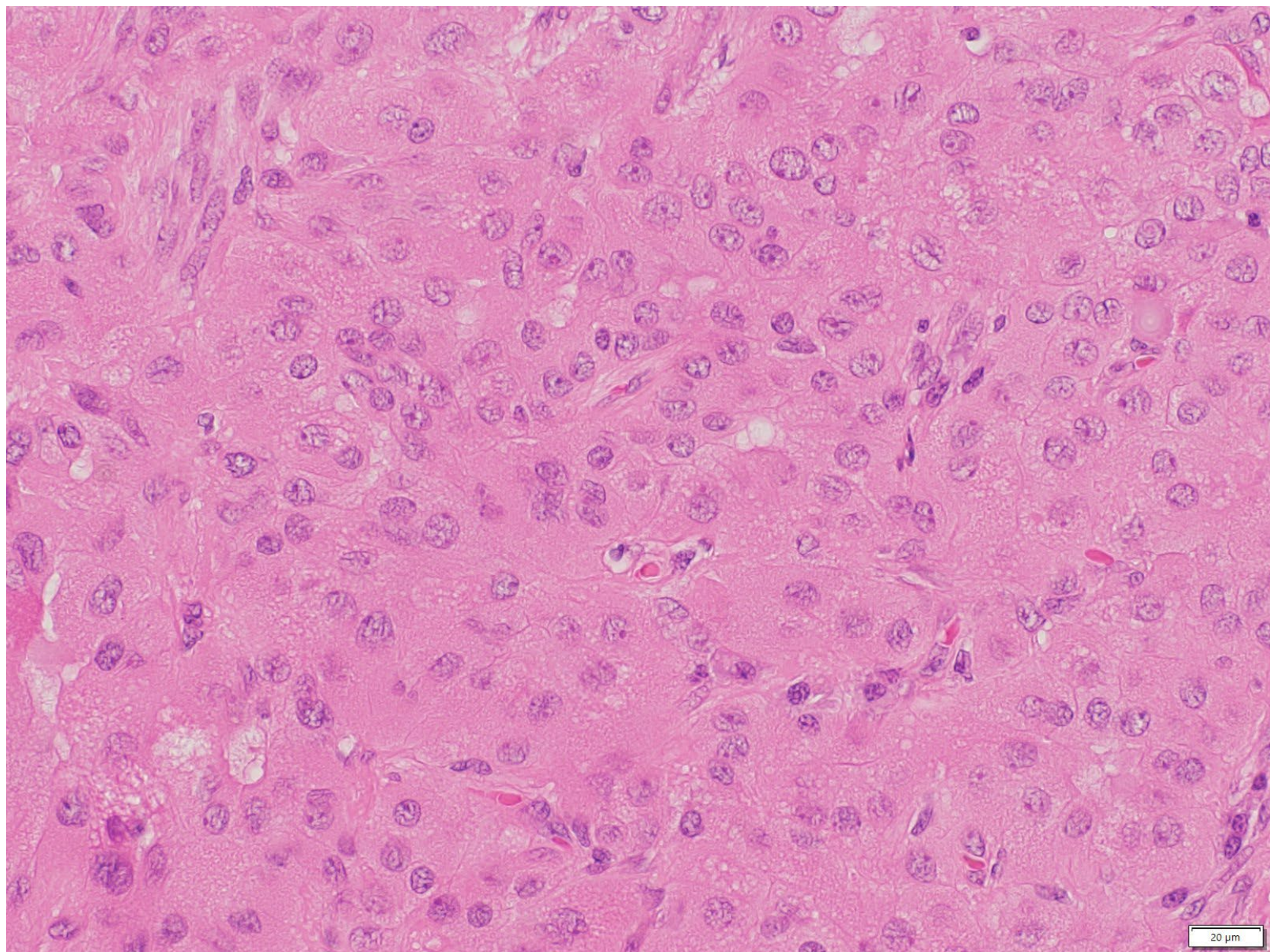
50 μm

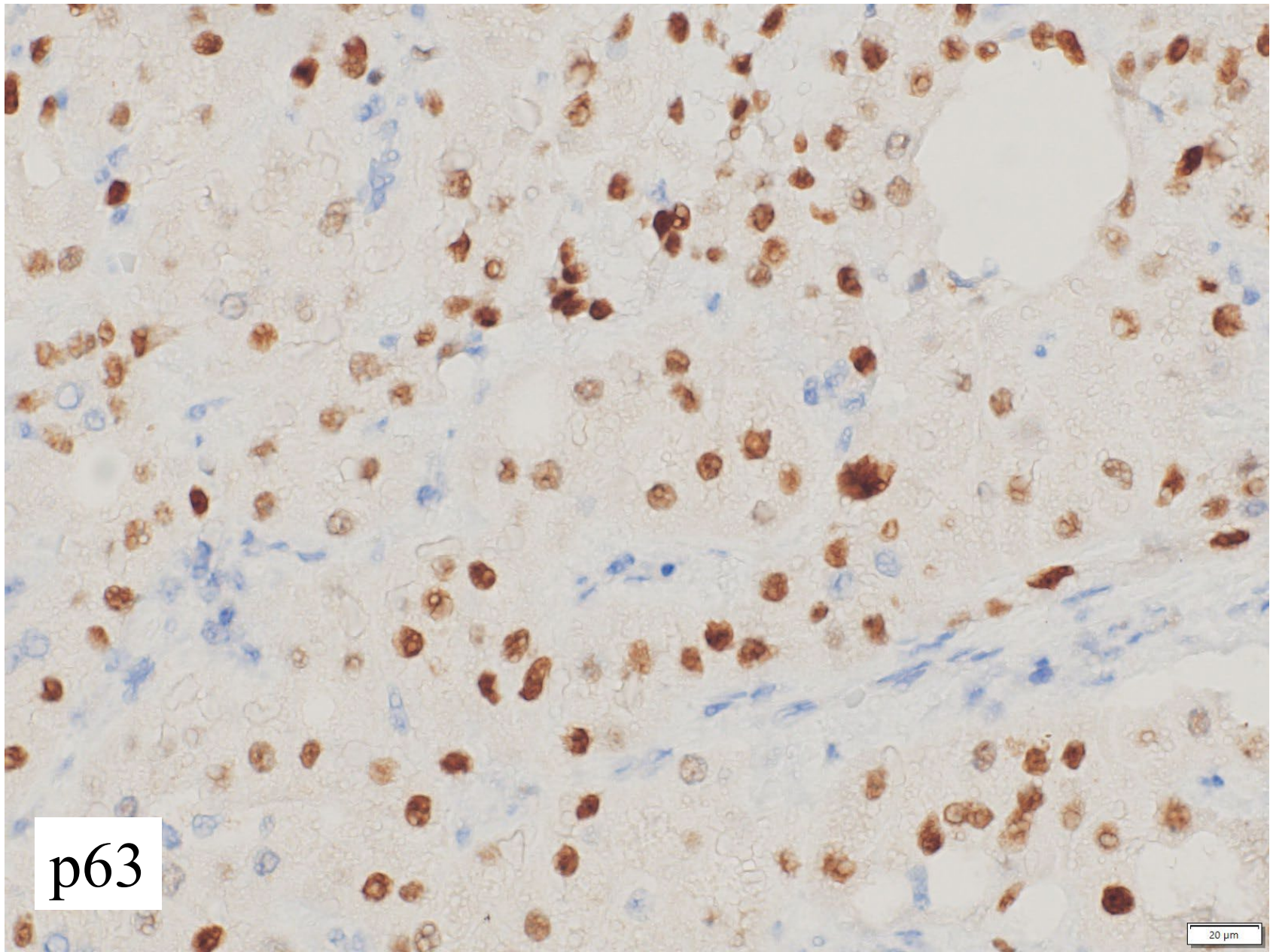
組織所見





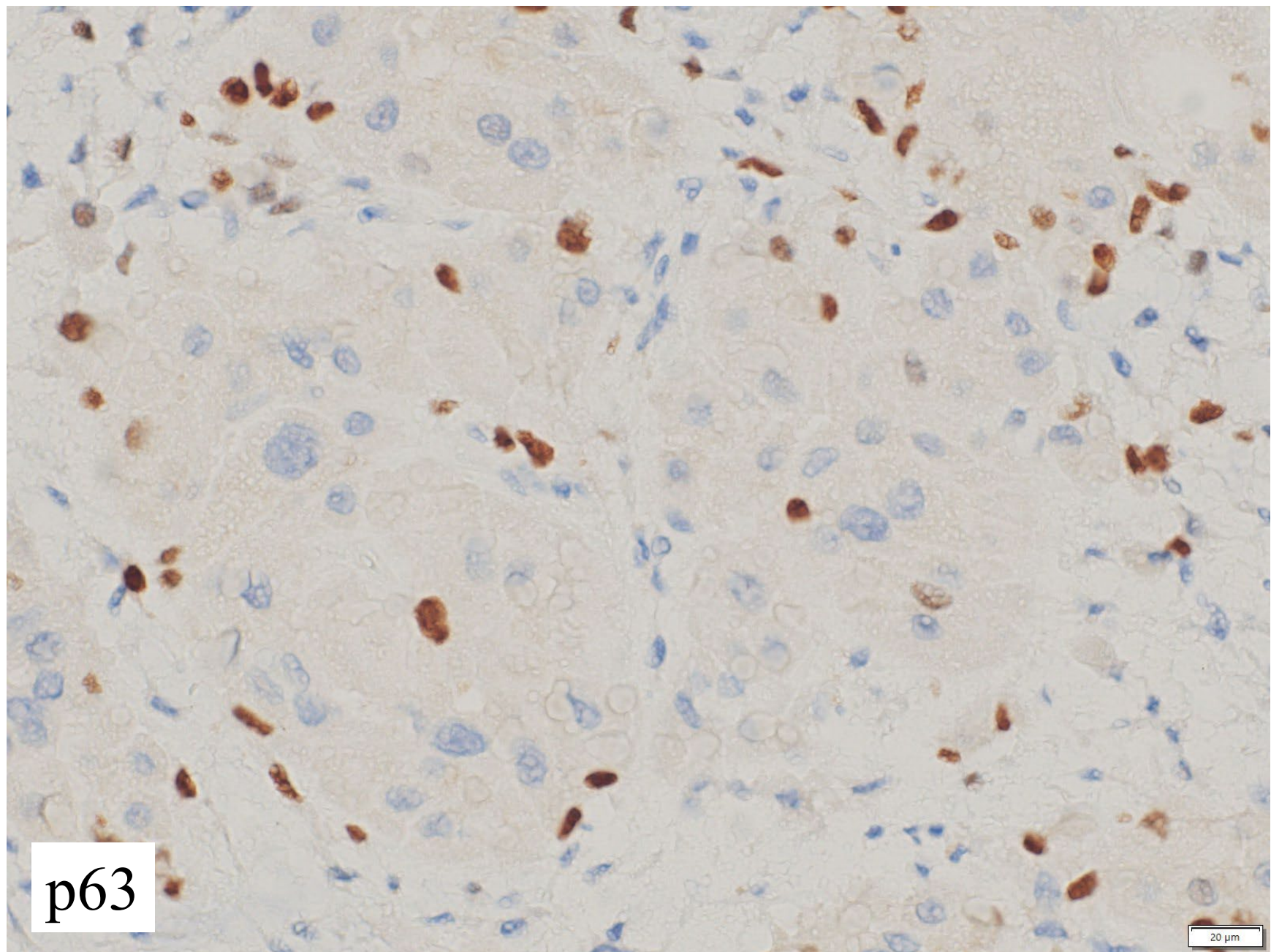






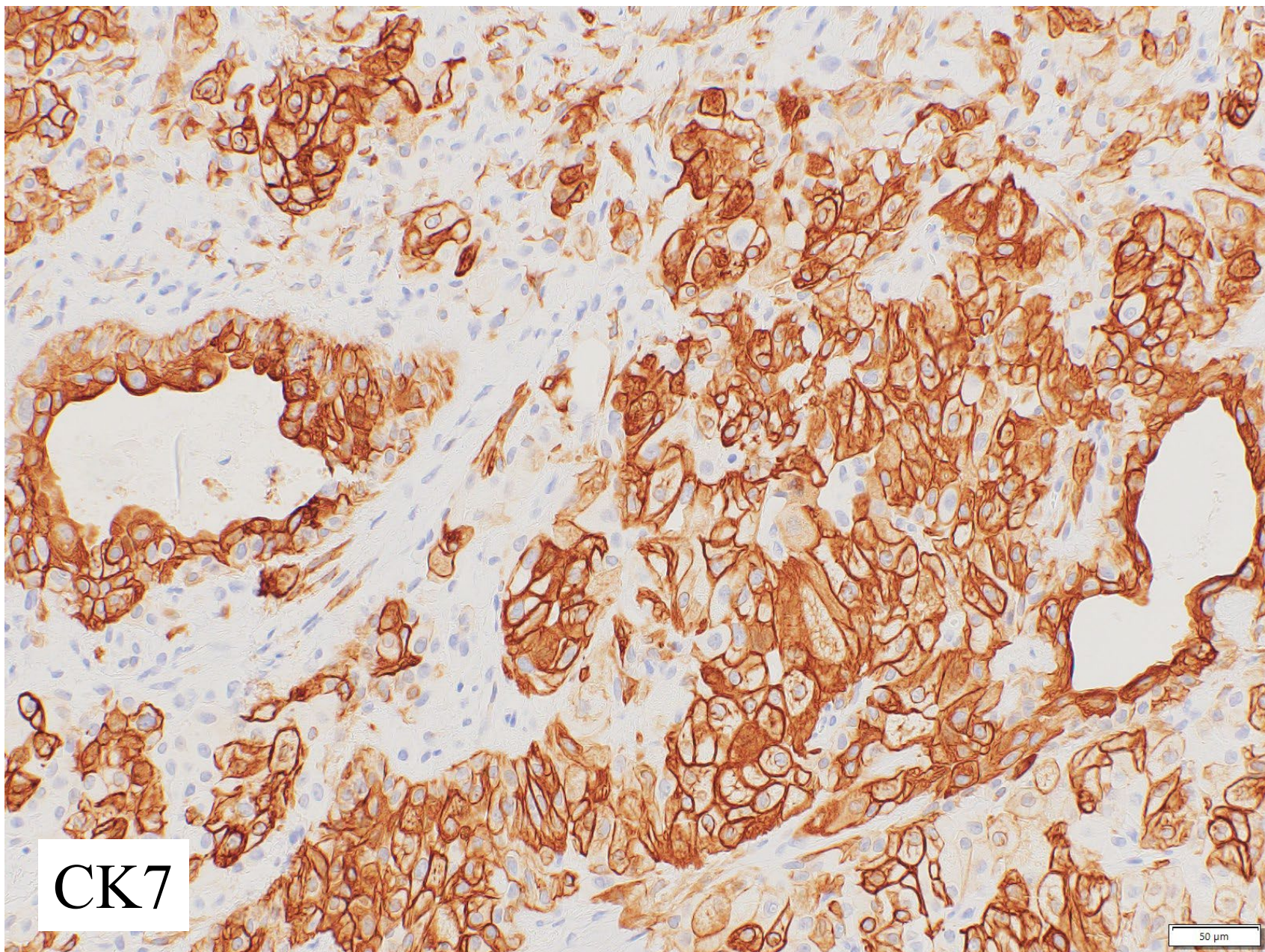
p63

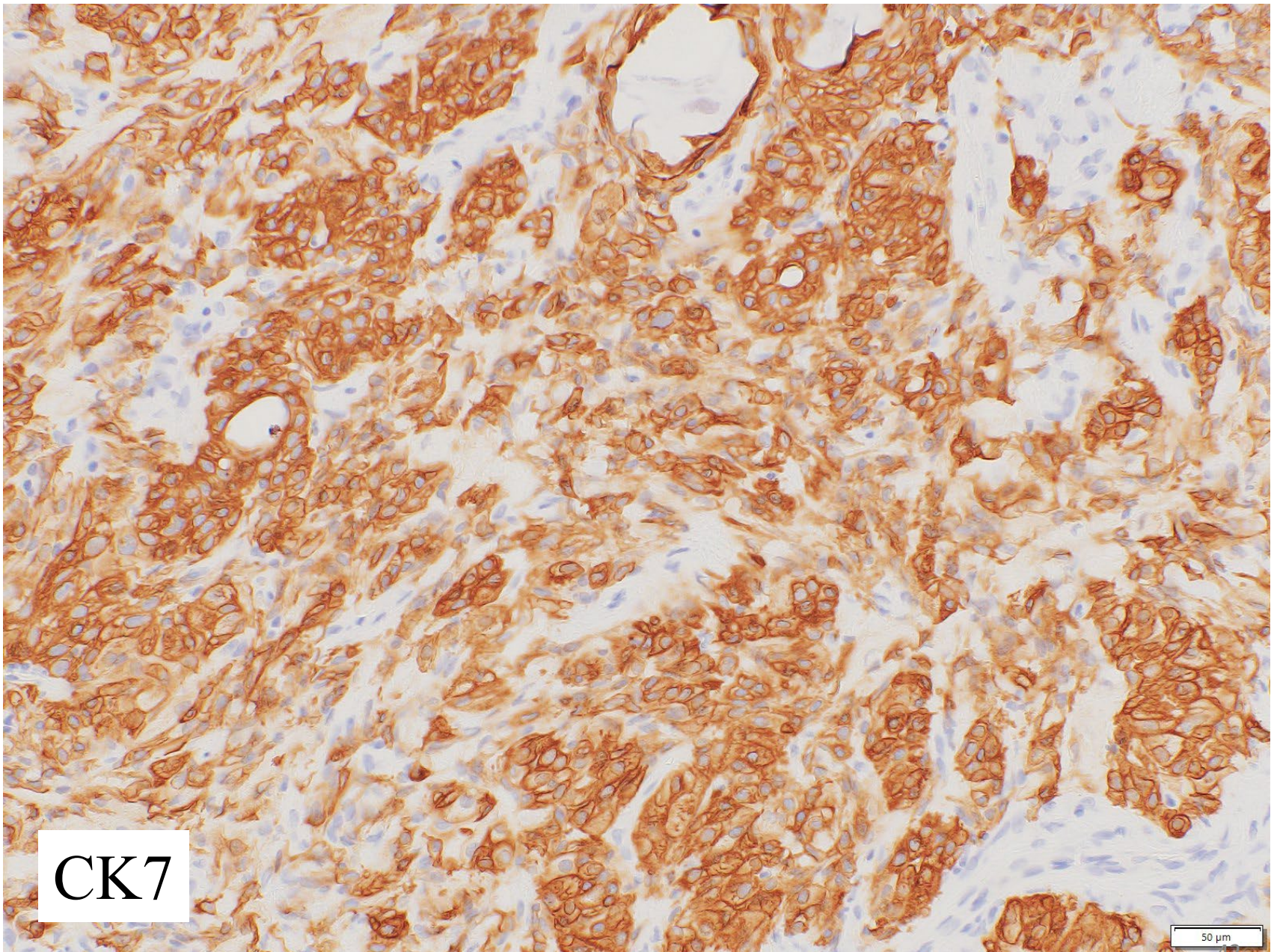
20 μm



p63

20 μm






CK7

50 μm

42

オンコサイト型多形腺腫

WHO Classification of Tumours [online](#) 

Head and Neck Tumours (5th ed.) // Chapter 4: Salivary gland tumours
// Benign epithelial tumours // Pleomorphic adenoma 

Pleomorphic adenoma

Definition

Pleomorphic adenoma (PA) is a benign epithelial neoplasm characterized by cytomorphological and architectural diversity, with an admixture of ductal and myoepithelial cells usually embedded in a chondromyxoid or fibrous stromal component.

ICD-O coding

8940/0 Pleomorphic adenoma

8940/3 Metastasizing pleomorphic adenoma

8940/0 Oncocytic pleomorphic adenoma

オンコサイト型多形腺腫

- オンコサイト型多形腺腫は主に好酸性顆粒を豊富に含む細胞で構成される
- オンコサイト型多形腺腫では、*PLAG1*遺伝子と*GEM*、*CHCHD7*、*NTF3*、*FBXO32*、*C1orf116*との融合が確認されている。*HMGA2*増幅も報告されている
- 免疫染色ではS100およびSOX10陽性所見が他のオンコサイト腫瘍との鑑別に有用である

作成者の許可なく複写、
転用を禁じます。

Unauthorized copying or
reproduction is prohibited.