

# A Case of Sinonasal Undifferentiated Carcinoma Successfully Responding to Chemoradiotherapy

Hirohide MATSUSHITA<sup>1)</sup>, Takesumi OZAWA<sup>1)</sup>, Nodoka SEKIGUCHI<sup>2)</sup>, Toshirou FUKUSHIMA<sup>2)</sup>  
Takashi KOBAYASHI<sup>2)</sup>, Shintaro KANDA<sup>2)</sup>\* and Tomonobu KOIZUMI<sup>2)</sup>

1) Department of Radiology, Shinshu University School of Medicine

2) Department of Comprehensive Cancer Therapy, Shinshu University School of Medicine

Sinonasal undifferentiated carcinoma is an extremely rare and high-grade neoplasm arising in the nasal cavity, with highly aggressive clinical behavior and poor prognosis. Multimodal therapies have been proposed, including surgery, radiotherapy, and chemotherapy, but a standard treatment strategy has not been determined because of its rarity. Here, we present a case of sinonasal undifferentiated carcinoma treated with cisplatin + etoposide chemotherapy combined with radiotherapy (2 Gy × 30 fractions, total 60 Gy). The patient achieved complete remission and is still alive without recurrence for over 5 years. A beneficial therapeutic outcome by chemoradiotherapy alone is extremely rare in patients with sinonasal undifferentiated carcinoma. *Shinshu Med J* 69: 121–126, 2021

(Received for publication June 16, 2020; accepted in revised form January 5, 2021)

**Key words**: undifferentiated carcinoma, FDG-PET, cisplatin VP-16, nasal cavity, complete remission

## I Introduction

Malignant tumors of the sinonasal tract are extremely rare, accounting for only 3 % of all head and neck cancers<sup>1)</sup>. Sinonasal tumors show similar clinical manifestations, such as nasal obstruction and epistaxis, but a wide range of histological features, including histogenesis and differentiation of tumor cells<sup>2)</sup>. Sinonasal undifferentiated carcinoma (SNUC), originally described by Frierson et al. in 1986<sup>3)</sup>, is an extremely rare and high-grade neoplasm arising in the nasal cavity with highly aggressive clinical behavior and poor prognosis<sup>1)-7)</sup>. In a study of 36 cases of SNUC, Jeng et al.<sup>8)</sup> reported that 17 % and 31 % of patients presented with cervical lymph node and distant metastasis, respectively, and had a median survival period of 10 months. Multimodal therapies have been

proposed for SNUCs, including surgery, radiotherapy, and chemotherapy, but a standard treatment strategy has not been determined because of its rarity. We encountered a case of locally advanced SNUC treated with cisplatin + etoposide chemotherapy combined with radiotherapy, which showed a survival period of >5 years without recurrence. Here, we describe the clinical course of this case along with a brief review of the relevant literature, focusing on diagnosis and treatment.

## II Case Presentation

A 71-year-old woman had presented with nasal obstruction and intermittent epistaxis from the left nasal cavity for the previous 3 months. She visited another hospital as she also had headache in addition to these symptoms. Computed tomography (CT) indicated a tumor mass in the left nasal cavity and the patient was referred to our hospital. On physical examination, swelling and hypoesthesia of the left upper jaw were observed. Cervical lymph nodes were not palpable. Laboratory findings, including

\* Corresponding author : Shintaro Kanda  
Department of Comprehensive Cancer Therapy,  
Shinshu University School of Medicine,  
3-1-1 Asahi, Matsumoto, Nagano 390-8621, Japan  
E-mail : skanda@shinshu-u.ac.jp

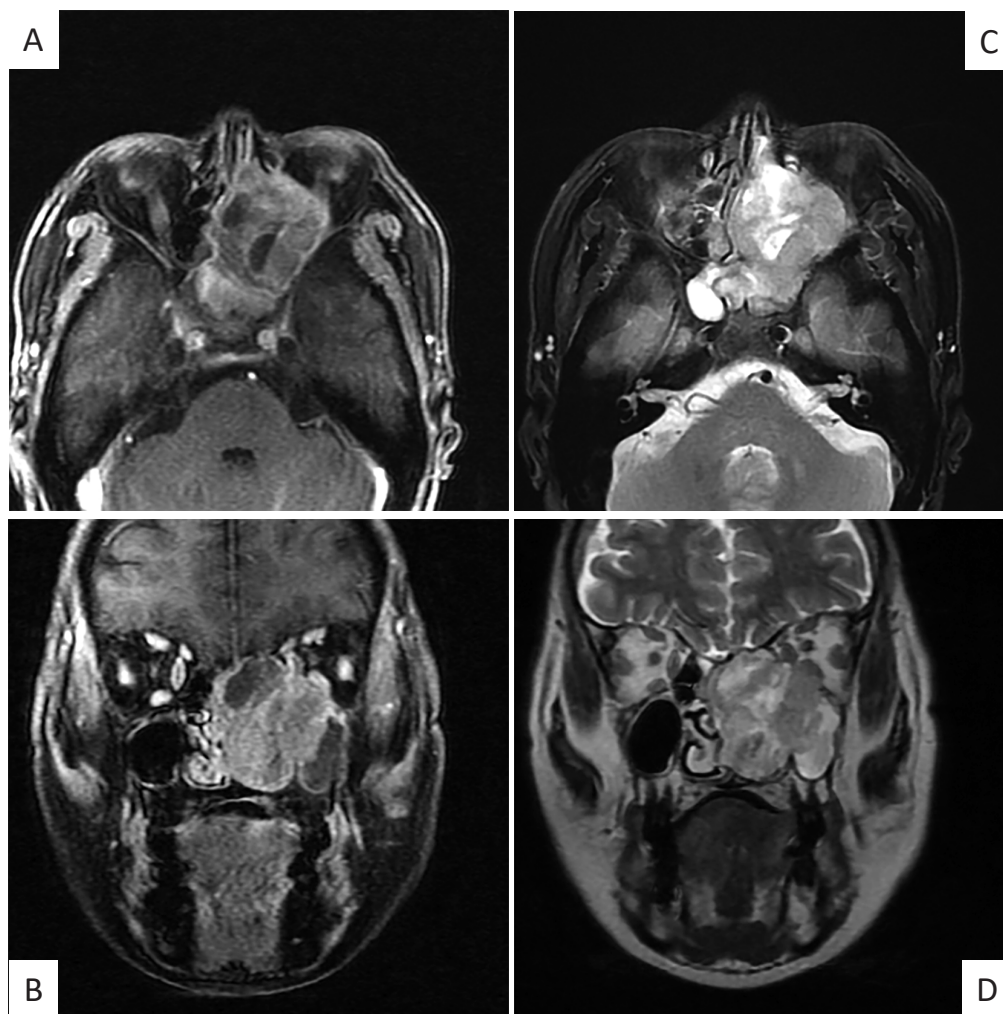


Fig. 1 Magnetic resonance imaging (MRI) at admission. Fat suppressed contrast-enhanced T1-weighted (A ; axial, B ; coronal), and T2-weighted (C ; axial, D ; coronal) images showing a heterogenous contrast-enhanced mass occupying the left nasal cavity and infiltrating the bones of the paranasal sinus.

tumor markers (CEA, CA19-9, SCC, NSE, and Pro-GRP), were within normal limits. CT and magnetic resonance imaging (MRI) showed a hypervascular mass occupying the left nasal cavity and infiltrating the bones of the paranasal sinus (**Fig. 1**). Tumor biopsy was performed, and the histological findings showed groups of atypical small round cells with hyperchromatic nuclei beneath the epithelium (**Fig. 2A, B**). The results of immunohistochemical analysis indicated that the atypical cells were negative for S-100 protein (**Fig. 2C**), chromogranin A (**Fig. 2D**), synaptophysin, neuron-specific enolase, melanoma-associated antigen 45 (**Fig. 2E**), CD 20, CD 34, CD 56 and  $\alpha$ -smooth muscle antigen, and positive for cytokeratin AE1/AE3, (**Fig. 2F**). In addition, tumor

cells were negative for nuclear protein in testis and p63 on immunohistochemical examination. Based on these histological findings, a diagnosis of SNUC was made. There were no regional lymph nodes and distant metastases on systemic radiographic examination including positron emission tomography with fluorodeoxyglucose-computed tomography (FDG-PET/CT). However, during the examinations, she developed further worsening and painful swelling of the left upper jaw. Left exophthalmos and diplopia were also present because of tumor growth. Surgical excision was impossible because of the locally advanced nature of the tumor. Chemotherapy was initiated with cisplatin at 80 mg/m<sup>2</sup> intravenously on day 1 and etoposide at 100 mg/m<sup>2</sup> intravenously on



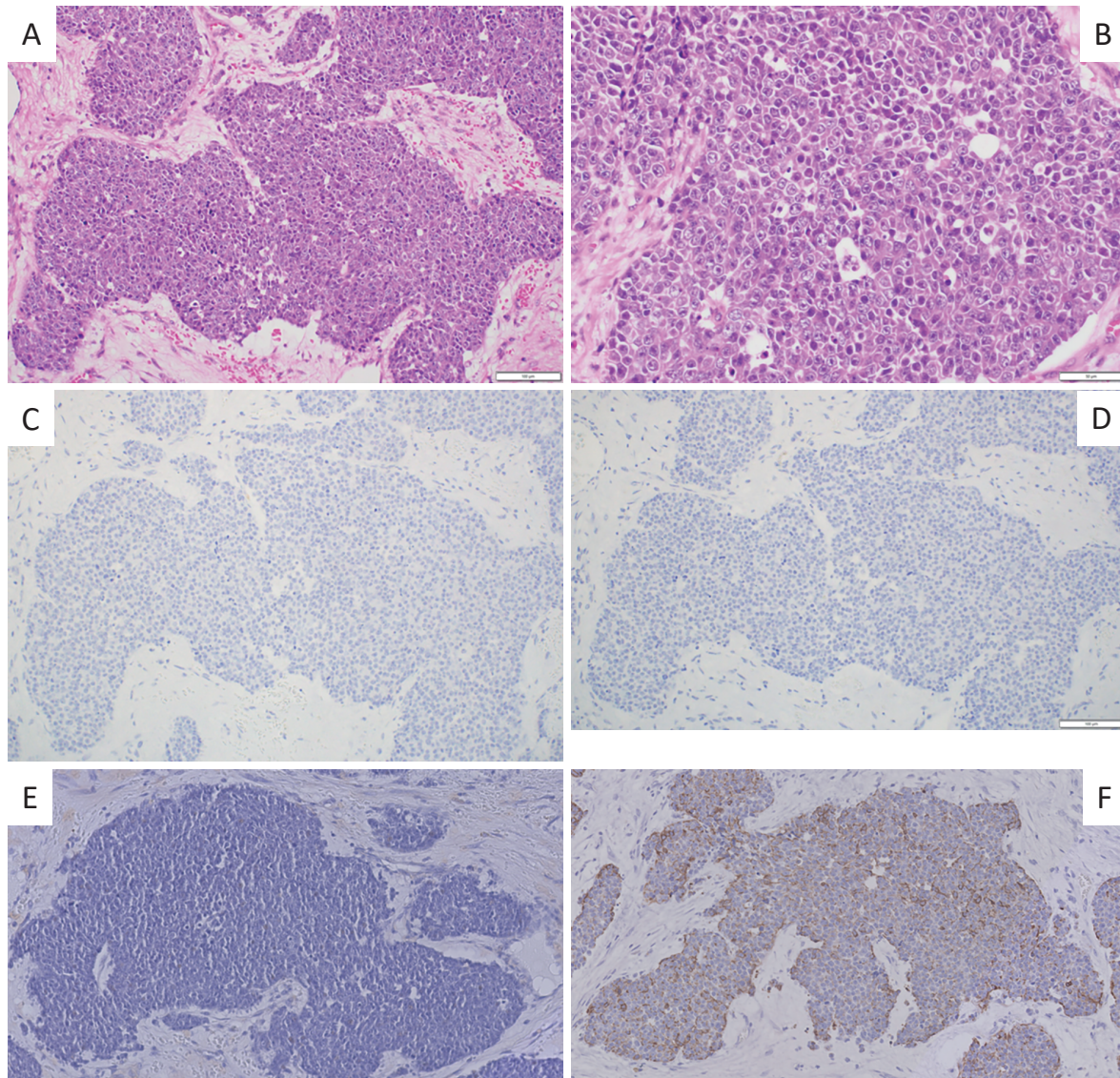


Fig. 2 Hematoxylin and eosin staining ; (A) low-power (x 2) and (B) high-power fields ( $\times 40$ ). Immunohistochemical findings indicated that malignant cells were negative for (C) S-100, (D) chromogranin A and (E) melanoma-associated antigen, and positive for (F) cytokeratin AE1/AE3.

days 1-3 (PE chemotherapy) every 3-4 weeks. Three cycles of PE chemotherapy were effective and resulted in tumor reduction (**Fig. 3A, B**). Subsequently, concurrent radiotherapy at a dose of 60 Gy in 30 fractions of 2.0 Gy each combined with PE chemotherapy was performed (**Fig. 3C, D**). Irradiation fields included primary tumor and bilateral neck as elective neck treatment. During the chemoradiotherapy, the patient developed febrile neutropenia but recovered with appropriate antibiotic therapy. The patient refused a fifth round of PE chemotherapy. FDG-PET/CT revealed negative FDG uptake after the chemoradiotherapy (**Fig. 3F**) and was considered to show com-

plete remission (**Fig. 3D, F**). Based on the FDG-PET findings, salvage surgery for the residual mass was not undertaken and close observation has been performed. The patient is still alive without recurrence for over 5 years.

### III Discussion

There are no specific clinical and radiographic findings that could be useful for differential diagnosis among nasal malignancies<sup>(8,9)</sup>. Therefore, a histological diagnosis is essential for high-grade malignancies because of the broad and complex histological findings in tumors arising from the sinonasal tract<sup>(1-6)</sup>.

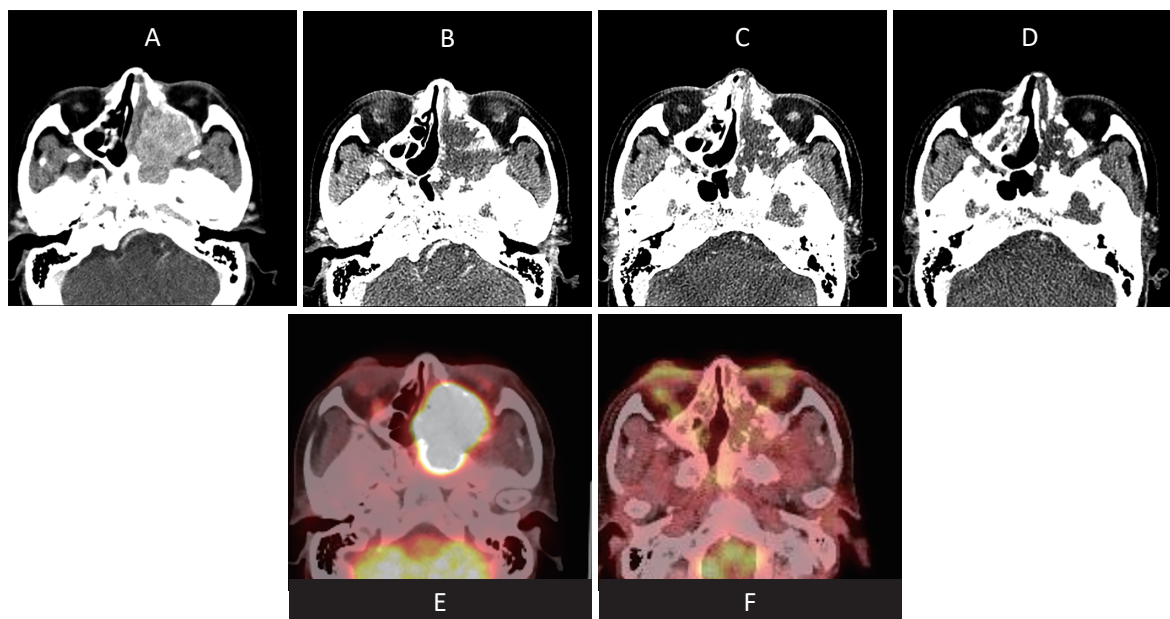


Fig. 3 Serial contrast-enhanced computed tomographies are shown, (A) before, (B) after three cycles of cisplatin plus etoposide chemotherapy, (C) after chemoradiotherapy by 4th cycle cisplatin plus etoposide combined with radiotherapy (60Gy) and (D) 4 years after the chemoradiotherapy. Positron emission tomography with fluorodeoxyglucose-computed tomography (FDG-PET/CT) (E) before and (F) after chemoradiotherapy. Positive FDG uptake in the nasal mass was completely diminished after the chemoradiotherapy, suggested complete remission after chemoradiotherapy.

The differential diagnoses of small round cell tumors include squamous cell carcinoma, small cell neuroendocrine carcinoma, rhabdomyosarcoma, Ewing sarcoma, lymphoma, malignant melanoma, etc. Immunohistological markers are useful for differential diagnosis<sup>4-6</sup>, and the tumor cells in the present case were of epithelial origin and lacked any evidence of neuroendocrine, muscle, melanocyte, or leukocyte differentiation. The histological findings in our case were consistent with those in other reports of SNUCs.

Multimodality therapy has been adopted for SNUC, but the optimal treatment has yet to be determined because of its rarity. Smith et al.<sup>6</sup> reported six patients with SNUCs initially treated with surgical resection followed by radiation therapy. Only two cases had disease-free survival of 6 and 18 months at last follow-up. On the other hand, Musy et al.<sup>7</sup> reported the clinical outcomes of 20 cases of SNUCs initially treated with chemoradiotherapy or radiotherapy. Ten cases were followed by craniofacial resection and the 2-year survival was 64 % in the treatment group. The study suggested that the response to initial chemoradiotherapy was important

for long-term survival. Recently, Faisal et al.<sup>10</sup> summarized clinical data of 255 published patients with SNUCs and reported that the locoregional control rate was 63.9 % undergoing trimodality (surgery plus radiotherapy with and without chemotherapy), 49.2 % in bimodality (chemoradiotherapy), and 31.3 % in surgery alone. There was no significant difference in the locoregional control rate between trimodality and bimodality in their study, however, the data suggested that surgical resection for residual tumor after chemoradiotherapy could be added for the best suitable management in the present case. However, several cases indicated that viable tumor cells in the resected specimens were absent after chemoradiotherapy and associated with relatively long survival<sup>6-8</sup>. In addition, the negative FDG-PET finding after chemoradiotherapy in our case suggested a complete remission. Several clinical studies suggested that if PET scan is negative by FDG-PET, salvage surgery or subsequent chemotherapy can be omitted safely in patients with seminoma<sup>11,12</sup> and/or malignant lymphoma<sup>13</sup>. Thus, treatment options in the present case including surveillance or salvage surgery, were em-



ployed and we selected close observation, resulting in long-term survival without recurrence over 5 years. Our case suggests that FDG-PET can be a useful tool for making a decision regarding optimal treatment choice for the residual mass in patients with SNUC. We need further clinical experience about the FDG-PET information and prognosis in patients with SNUC.

Faisal et al.<sup>10)</sup> also performed a meta-analysis assessing regional (neck) relapse with and without elective neck treatments (neck dissection or irradiation) and reported that the elective neck treatment was associated with an 80 % decreased risk for regional recurrence. Thus, elective neck treatment should be considered in patients with SNUC even in initial stage N0, as done in the present case.

In the present case, radiotherapy for all involved tumor lesions would have been difficult because of the wide fields, especially when including the left orbit area. Therefore, we selected PE chemotherapy alone as the initial therapy. The efficacy of this PE chemotherapy was remarkable and concurrent chemoradiotherapy was available after three cycles of PE chemotherapy. No information is available in the literature regarding the usefulness of chemotherapy in SNUCs. Various chemotherapeutic regimens, including CDDP +5-FU, cyclophosphamide, vincris-

tine, doxorubicin (CAF), or PE, were used in previous case series<sup>4)-8)</sup>. However, these studies did not evaluate the response. PE combined with concurrent radiotherapy has been widely accepted in limited cases of small cell lung cancer<sup>14)</sup>. In addition, radiotherapy combined with PE chemotherapy was used in the treatment of other nasal tumors<sup>15)-17)</sup>. Our experience suggested that PE is a useful novel chemotherapy regimen for SNUC. Further clinical studies of SNUC and evaluation of the response to chemoradiotherapy or chemotherapy are required.

#### IV Conclusion

We described a case of SNUC successfully treated with chemoradiotherapy alone, resulting in complete remission and disease-free survival for over 5 years. The disease of SNUC should be recognized and differential diagnosis of this distinct tumor from other nasal tumors is important. FDG-PET may be a useful for making a decision regarding optimal treatment choice in patients with SNUCs.

#### Conflict of Interest

The authors declare no potential conflicts of interest with respect to the research, authorship, and/or publication of this article.

#### References

- 1) Goel R, Ramalingam K, Ramani P, Chandrasekar T : Sino nasal undifferentiated carcinoma : A rare entity. *J Nat Sci Biol Med* 3 : 101-104, 2012
- 2) Devi CP, Devi KM, Kumar P, Amrutha Sindhu RV : Diagnostic challenges in malignant tumors of nasal cavity and paranasal sinuses. *J Oral Maxillofac Pathol* 23 : 378-382, 2019
- 3) Frierson HF Jr, Mills SE, Fechner RE, Taxy JB, Levine PA : Sinonasal undifferentiated carcinoma. An aggressive neoplasm derived from schneiderian epithelium and distinct from olfactory neuroblastoma. *Am J Surg Pathol* 10 : 771-779, 1986
- 4) Ejaz A, Wenig BM : Sinonasal undifferentiated carcinoma : clinical and pathologic features and a discussion on classification, cellular differentiation, and differential diagnosis. *Adv Anat Pathol* 12 : 134-143, 2005
- 5) Enepekides DJ : Sinonasal undifferentiated carcinoma : an update. *Curr Opin Otolaryngol Head Neck Surg* 13 : 222-225, 2005
- 6) Smith SR, Som P, Fahmy A, Lawson W, Sacks S, Brandwein M : A clinicopathological study of sinonasal neuroendocrine carcinoma and sinonasal undifferentiated carcinoma. *Laryngoscope* 110(10 Pt 1) : 1617-1622, 2000
- 7) Musy PY, Reibel JF, Levine PA : Sinonasal undifferentiated carcinoma : the search for a better outcome. *Laryngoscope* 112(8 Pt 1) : 1450-1455, 2002

- 8) Jeng YM, Sung MT, Fang CL, et al : Sinonasal undifferentiated carcinoma and nasopharyngeal-type undifferentiated carcinoma : two clinically, biologically, and histopathologically distinct entities. *Am J Surg Pathol* 26 : 371-376, 2002
- 9) Phillips CD, Futterer SF, Lipper MH, Levine PA : Sinonasal undifferentiated carcinoma : CT and MR imaging of an uncommon neoplasm of the nasal cavity. *Radiology* 202 : 477-480, 1997
- 10) Faisal M, Seemann R, Lill C, et al : Elective neck treatment in sinonasal undifferentiated carcinoma : Systematic review and meta-analysis. *Head Neck* 42 : 1057-1066, 2020
- 11) Bachner M, Loriot Y, Gross-Goupil M, et al :  $2\text{-}^{18}\text{F}$ -fluoro-deoxy-D-glucose positron emission tomography (FDG-PET) for postchemotherapy seminoma residual lesions : a retrospective validation of the SEMPET trial. *Ann Oncol* 23 : 59-64, 2012
- 12) Sakaguchi Y, Isowa N : Successful resection of mediastinal seminoma evaluated the response to induction chemotherapy with fluorodeoxyglucose-positron emission tomography. *Ann Thorac Cardiovasc Surg* 18 : 45-47, 2012
- 13) Johnson P, Federico M, Kirkwood A, et al : Adapted Treatment Guided by Interim PET-CT Scan in Advanced Hodgkin's Lymphoma. *N Engl J Med* 374 : 2419-2429, 2016
- 14) Stinchcombe TE, Gore EM : Limited-stage small cell lung cancer : current chemoradiotherapy treatment paradigms. *Oncologist* 15 : 187-195, 2010
- 15) Gomi D, Sasaki S, Sekiguchi N, Kobayashi T, Sakamoto A, Koizumi T : A case of olfactory neuroblastoma (esthesioneuroblastoma) presenting with anemia due to nasal bleeding. *Shinshu Med J* 64 : 247-252, 2016
- 16) Lucas JT Jr, Ladra MM, MacDonald SM, et al : Proton therapy for pediatric and adolescent esthesioneuroblastoma. *Pediatr Blood Cancer* 62 : 1523-1528, 2015
- 17) Nakamura Y, Suzuki M, Ozaki S, et al : Sinonasal inverted papilloma associated with small cell neuroendocrine carcinoma : A case report and literature review of rare malignancies associated with inverted papilloma. *Auris Nasus Larynx* 46 : 641-650, 2019

(2020. 6. 16 received ; 2021. 1. 5 accepted)

---