

Complete Response to S-1 Monotherapy Over 3 Years in an Elderly Patient with Advanced Non-Small-Cell Lung Cancer

Kazuhisa URUSHIHATA^{1)*}, Toshihiko AGATSUMA¹⁾, Toshiki YOKOYAMA¹⁾
Michiko ITOU¹⁾, Keishi KUBO¹⁾, Tomonobu KOIZUMI²⁾ and Hisashi SHIMOJO³⁾

1) *First Department of Internal Medicine, Shinshu University School of Medicine*

2) *Comprehensive Cancer Center, Shinshu University School of Medicine*

3) *Department of Laboratory Medicine, Shinshu University School of Medicine*

The number of elderly patients with cancer continues to increase. The optimal chemotherapeutic regimen for inoperable non-small-cell lung cancer (NSCLC) in elderly patients, especially over 80 years old, remains controversial. S-1, a newly developed oral fluorouracil antitumor drug, has been reported to be effective in the treatment of gastrointestinal and pancreatic tumors and/or NSCLC. We experienced a case of an elderly patient with advanced-stage NSCLC who responded well to S-1 monotherapy with tolerable toxicities and has had three years of disease-free survival. S-1 appears to have significant activity with mild toxicities for selected elderly NSCLC patients and in our view warrants further clinical study. *Shinshu Med J 59 : 321—325, 2011*

(Received for publication March 28, 2011 ; accepted in revised form June 6, 2011)

Key words : chemotherapy, elderly, lung cancer

I Introduction

Lung cancer is the leading cause of cancer-related deaths in Japan and throughout the Western world¹⁾²⁾. Approximately 50 % of patients diagnosed with or dying from non-small-cell lung cancer (NSCLC) are 70 years or older around the world¹⁾⁻³⁾. In general, doublet combinations of platinum compounds are standard regimens as first-line treatment in advanced-stage NSCLC⁴⁾⁻⁶⁾. There are a number of platinum-based clinical trials ; however, only 13-17 % of patients over 70 years old were enrolled in these studies⁶⁾⁷⁾. In addition, it has not been demonstrated that platinum-containing regimens could actually increase the survival in elderly patients with advanced NSCLC. Thus, the effective treatment options for elderly patients are extremely limited because of the lack of clinical trials for the

elderly population, especially the patients over 80 years old.

S-1 (Taiho Pharmaceutical Co., Tokyo, Japan) is a novel oral fluoropyrimidine derivative consisting of tegafur and two modulators, 5-choloro2, 4-dihydroxypyridine and potassium oxonate, in a molar ratio of 1 : 0.4 : 1. S-1 has been available for several solid malignancies including gastric cancer, pancreatic cancer and NSCLC. In this report, we describe a case of advanced NSCLC aged 80 years, who showed complete response to S-1 monotherapy and prolonged disease-free survival for 3 years.

II Case report

An 80-year-old man presented with a two-month history of exertional dyspnea and anterior chest pain during sleeping for the previous two months. He visited our hospital in January 2008. His body height and weight were 155 cm and 45.5 kg, respectively. There was no weight loss and performance status was good. Physical examinations were unremarkable. Laboratory data including

* Corresponding author : Kazuhisa Urushihata
First Department of Internal Medicine, Shinshu University School of Medicine, 3-1-1 Asahi, Matsumoto-city, Nagano-prefecture 390-8621, Japan

hematology, chemistry, and tumor markers were within normal limits, although the inflammatory parameter (CRP) was positive (Table 1). Chest computed tomography (CT) revealed a mass in the right upper lobe and the swelling of hilar lymphadenopathy (Fig. 1A). Bronchofiberscopy was performed and the cytological findings revealed malignant cells suggesting large-cell carcinoma or poorly differentiated adenocarcinoma (Fig 2). Epidermal growth factor receptor mutation was not found in the specimens. Systemic evaluations including ^{18}F -fluorodeoxyglucose positron emission tomography were performed, and the clinical stage was estimated as the locally advanced and inoperable stage (III B). The present case was treated with S-1 monotherapy after written informed consent. The schedule of administration of S-1 was orally at a

dose of 80 mg/m² every two weeks with a two-week drug-free interval. During S-1 administration, appetite loss (grade 1) and leukocytopenia (grade 1) were sometimes observed, but neither severe hematological nor non-hematological toxicities, requiring cessation or postponing of the agent were observed for about three years. In regard to the tumor responses, the tumor in the right upper lobe and hilar lymphadenopathy disappeared from the chest CT (Fig. 1B). S-1 therapy has been continued and the patient remains well with complete response status.

III Discussion

We reported our clinical experience with a patient of 80 years who showed a complete response to S-1 monotherapy over 3 years. Clinically, we inevitably encounter difficulty in the treatment of advanced NSCLC in elderly patients. Whereas the population of such patients had been increasing, the inadequacy of a consistent approach to treatment is becoming increasingly apparent. Thus, the question of how best to treat elderly NSCLC patients is becoming increasingly important.

There have been some clinical studies focusing on the effectiveness of chemotherapy in the over-seventies population. Initially, the Elderly Lung Cancer Vinorelbine Italian Study Group reported significantly superior survival and quality of life (QOL) with single-agent vinorelbine over best supportive care⁸⁾. Subsequently, a Japanese group conducted a randomized phase III study evaluating the efficacy and safety of docetaxel versus vinorelbine in elderly NSCLC patients⁹⁾. Although docetaxel monotherapy failed to show overall survival benefit in that study, it did improve progression-free survival, response rate and disease-related symptoms versus vinorelbine. Thus, single agent chemotherapy has been recommended for elderly patients with NSCLC. However, since the frequencies of enrolled patients over 80 years in these studies were too small (10–15%)⁸⁾⁹⁾, the optimal agent or the indications for chemotherapy in patients over 80 remain unclear.

Table 1 Laboratory data on admission

<u>Hematology</u>	
WBC	6680/ μL
RBC	399×10^4 / μL
Hb	11.6 g/dL
Ht	36.1 %
Platelet	28.2×10^4 / μL
<u>Chemistry</u>	
Total protein	6.8 g/dL
Albumin	3.0 g/dL
BUN	15 mg/dL
Creatinine	0.70 mg/dL
AST	17 IU/L
ALT	11 IU/L
LDH	188 IU/L
ALP	250 IU/L
γ -GTP	12 IU/L
T.Bil	0.66 mg/dL
Na	140 mEq/L
K	4.2 mEq/L
Cl	108 mEq/L
Ca	7.9 mg/dL
Glucose	136 mg/dL
CRP	1.10 mg/dL
<u>Tumor markers</u>	
CEA	1.5 ng/mL (<3.5)
CA19-9	25.0 U/mL (<37.0)
SCC	1.3 ng/mL (<2.0)

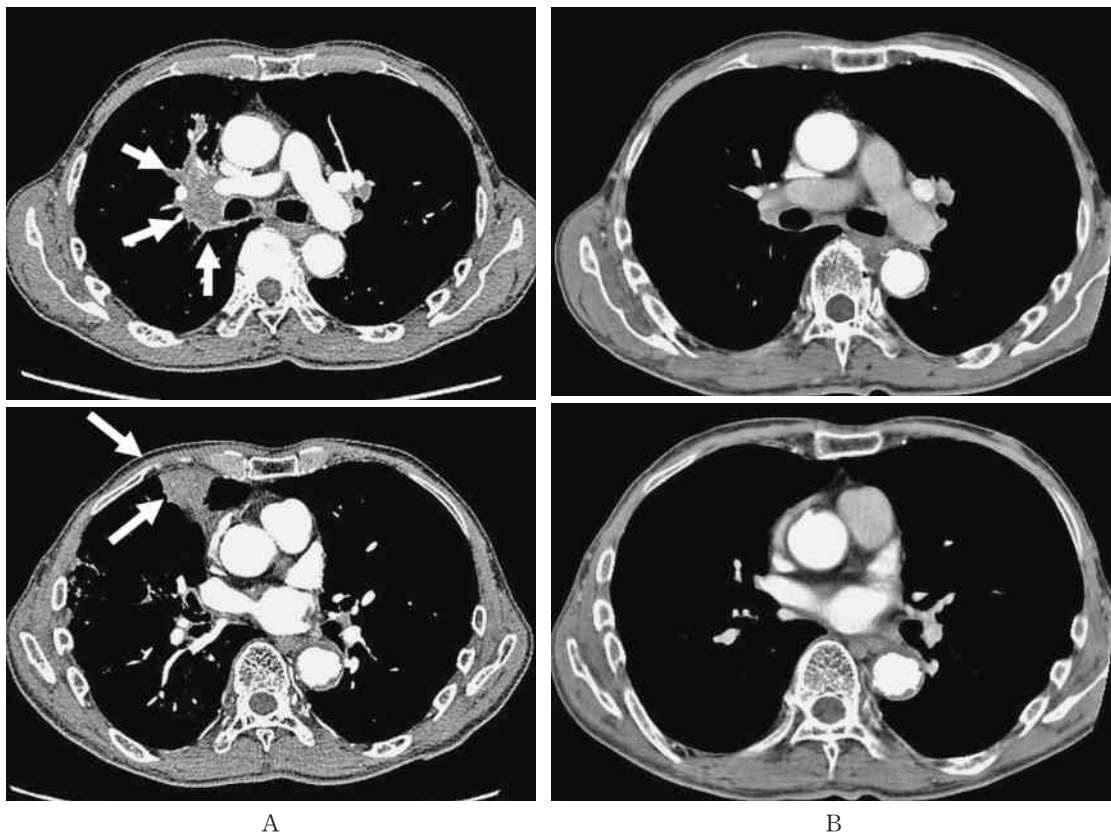


Fig. 1 Chest computed tomography before (A) and after (B) S-1 mono-chemotherapy. A; before chemotherapy, swelling of right hilar lymphadenopathy and mass in right upper lung fields. B; three years after S-1 monotherapy. The lymphadenopathy and mass have disappeared after S-1 mono-chemotherapy over three years (B).

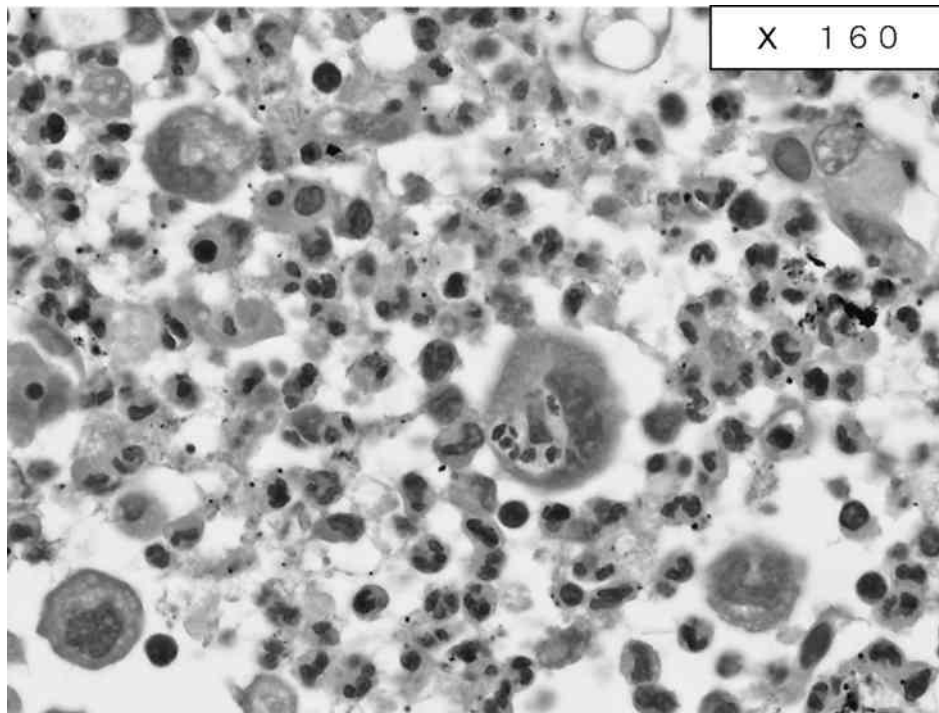


Fig. 2 Cytological findings taken from bronchofiberscopy revealed large-sized tumor cells with hyperchromatic nucleoli and emperipolesis, suggesting a large-cell carcinoma or poorly differentiated adenocarcinoma.

In the field of NSCLC, in a phase II trial of S-1¹⁰⁾ 59 advanced NSCLC patients without a previous history of chemotherapy were orally administered S-1 at approximately 40 mg/m² twice a day for 28 days, followed by a 2-week drug-free period. The response rate (RR) and median survival time (MST) were 22 % and 10.2 months, respectively. As expected, the incidence of severe gastrointestinal toxicities was low, and in regard to the hematologic toxicities, there were few severe events. Major adverse events with S-1 were gastrointestinal toxicity and myelosuppression, and both were reported to be mild in a phase II study conducted in patients with chemo-naïve advanced NSCLC: grade 3 or 4 neutropenia, 6.8 %; diarrhea, 8.5 %; stomatitis, 1.7 % (1/59). Thus, S-1 was considered to be active for NSCLC with fewer toxicities¹⁰⁾¹¹⁾. Although the study was done in patients under 75 years old, S-1 might be a novel therapy especially in elderly patients with NSCLC because of the fewer toxicities.

It has been demonstrated that the anticancer activity of S-1 is closely related to the intratumoral expression of dihydropyrimidine dehydrogenase

and thymidylate synthase¹²⁾¹³⁾. Unfortunately, histological analysis is unavailable in the present study because of the small sample. However, the complete response to S-1 and prolonged disease-free survival over 3 years in the present case is an extremely rare and encouraging experience. Based on our experience, we would like to emphasize that S-1 may be useful as an alternative chemotherapy agent for elderly patients with advanced NSCLC. There have been no prospective studies for evaluating the clinical usefulness of S-1 in elderly patients with NSCLC. Further clinical experiences and studies are required to fully determine the therapeutic benefit of S-1 in unresectable NSCLC in elderly patients.

In summary, based on the clinical results in several trials including our case, S-1 monotherapy may be considered as an option in the treatment of advanced NSCLC in the elderly. This novel agent merits further clinical investigation for the treatment of elderly patients with NSCLC. The information obtained from this case might provide a new direction for clinical trials on the treatment of inoperable NSCLC in the elderly.

References

- 1) Matsuda T, Marugame T, Kamo KI, Katanoda K, Ajiki W, Sobue T: The Japan Cancer Surveillance Research Group. Cancer incidence and incidence rates in Japan in 2005: based on data from 12 population-based cancer registries in the Monitoring of Cancer Incidence in Japan (MCIJ) Project. *Jpn J Clin Oncol* 41: 139-147, 2011
- 2) Marugame T, Matsuda T: Comparison of time trends in lung cancer incidence (1973-2002) in Asia, from cancer incidence in five continents Vols IV-IX. *Jpn J Clin Oncol* 39: 133-135, 2009
- 3) Lee-Chiong TL Jr, Matthay RA: Lung cancer in the elderly patient. *Clin Chest Med* 14: 453-478, 1993
- 4) American Society of Clinical Oncology Clinical Practice Guideline Update on Chemotherapy for Stage IV Non-Small Cell Lung Cancer November 16, 2009
- 5) Schiller JH, Harrington D, Belani CP, Langer C, Sandler A, Krook J, Zhu J, Johnson DH: Eastern Cooperative Oncology Group. Comparison of four chemotherapy regimens for advanced non-small-cell lung cancer. *N Engl J Med* 346: 92-98, 2002
- 6) Langer CJ, Manola J, Bernardo P, Kugler JW, Bonomi P, Cella D, Johnson DH: Cisplatin-based therapy for elderly patients with advanced non-small-cell lung cancer: implications of Eastern Cooperative Oncology Group 5592, a randomized trial. *J Natl Cancer Inst* 94: 173-181, 2002
- 7) Provencio M, Camps C, Alberola V, Massutti B, Viñolas N, Isla D, Dómine M, Millán I, Cobo M, Rosell R: Lung cancer and treatment in elderly patients: The Achilles Study. *Lung Cancer* 66: 103-106, 2009
- 8) The Elderly Lung Cancer Vinorelbine Italian Study (ELVIS) Group: Effects of vinorelbine on quality of life and survival of elderly patients with advanced non-small cell lung cancer. *J Natl Cancer Inst* 91: 66-72, 1999

- 9) Kudoh S, Takeda K, Nakagawa K, Takada M, Katakami N, Matsui K, Shinkai T, Sawa T, Goto I, Semba H, Seto T, Ando M, Satoh T, Yoshimura N, Negoro S, Fukuoka M: Phase III study of docetaxel compared with vinorelbine in elderly patients with advanced non-small-cell lung cancer: results of the West Japan Thoracic Oncology Group Trial (WJTOG 9904). *J Clin Oncol* 24 : 3657-3663, 2006
- 10) Kawahara M, Furuse K, Segawa Y, Yoshimori K, Matsui K, Kudoh S, Hasegawa K, Niitani H : S-1 Cooperative Study Group. Phase II study of S-1, a novel oral fluorouracil, in advanced non-small-cell lung cancer. *Br J Cancer* 85 : 939-943, 2001
- 11) Okamoto I, Fukuoka M : S-1 : a new oral fluoropyrimidine in the treatment of patients with advanced non-small-cell lung cancer. *Clin Lung Cancer* 10 : 290-294, 2009
- 12) Takiuchi H, Kawabe S, Gotoh M, Katsu K : Thymidylate synthase gene expression in primary tumors predicts activity of S-1-based chemotherapy for advanced gastric cancer. *Gastrointest Cancer Res* 1 : 171-176, 2007
- 13) Shimizu T, Yamada Y, Yasui H, Shirao K, Fukuoka M : Clinical application of immunoreactivity of dihydropyrimidine dehydrogenase (DPD) in gastric scirrhous carcinoma treated with S-1, a new DPD inhibitory fluoropyrimidine. *Anticancer Res* 25 : 2997-3001, 2005

(2011. 3. 28 received ; 2011. 6. 6 accepted)
