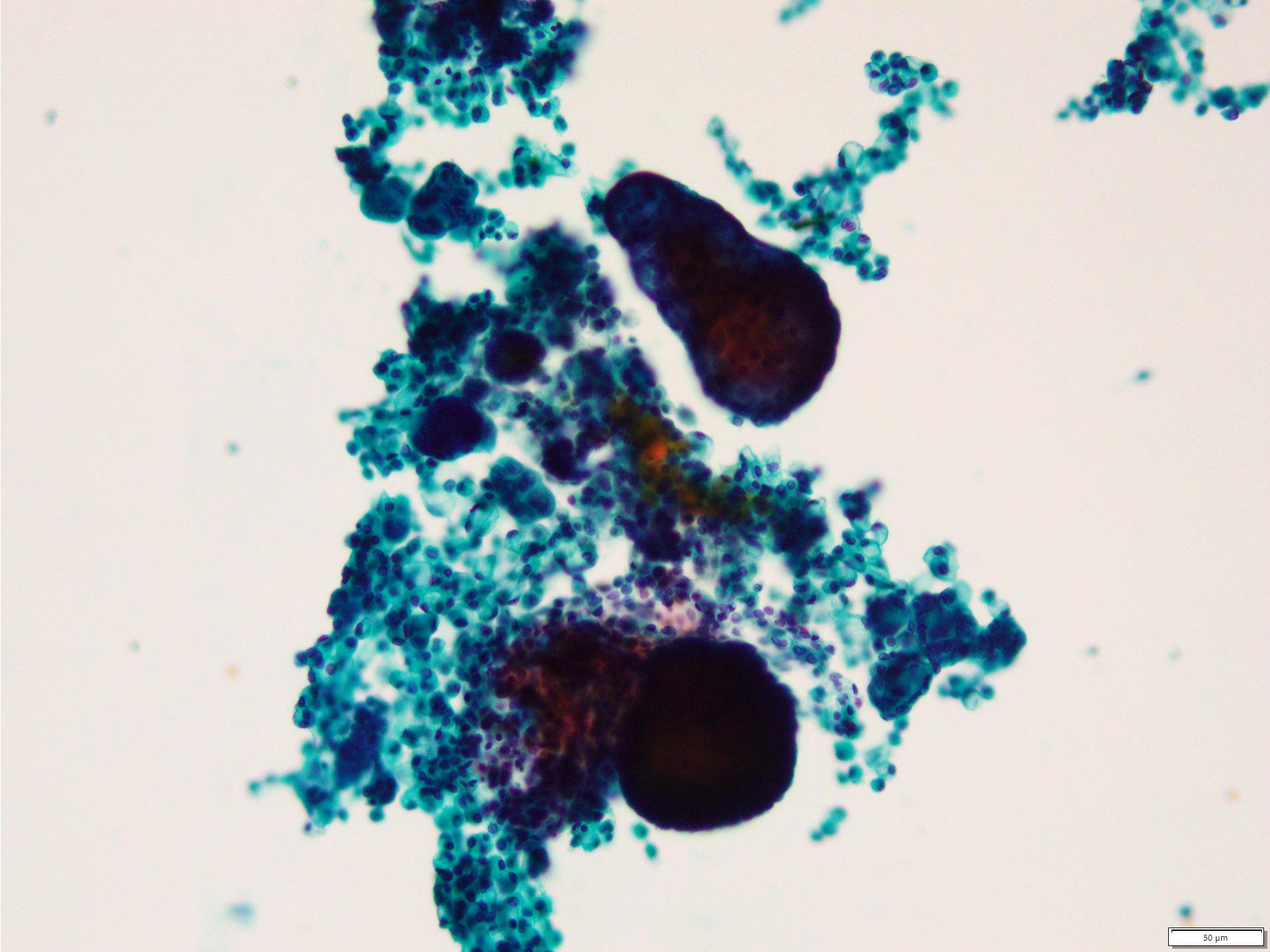
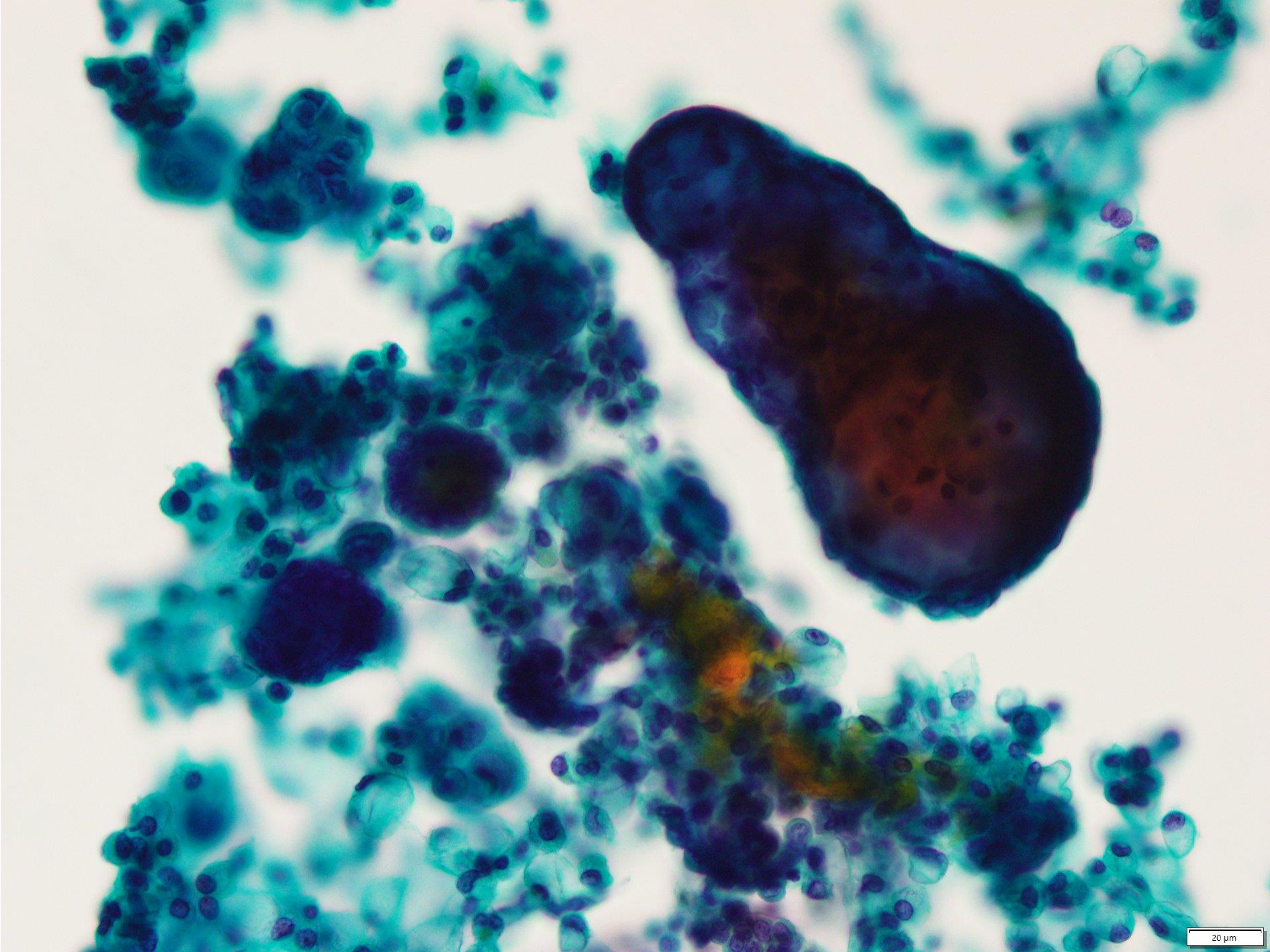


# 体腔液症例

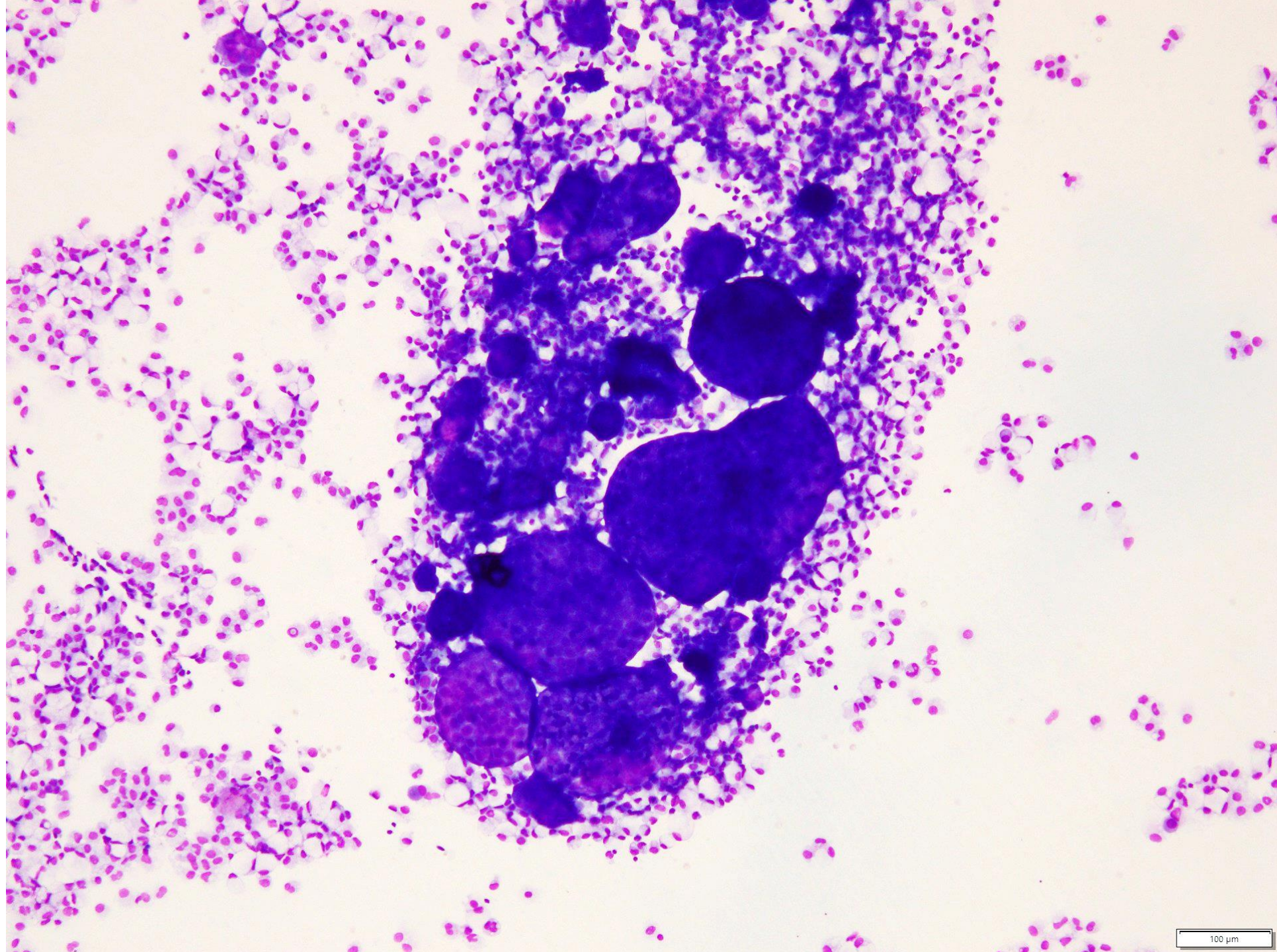
- 年齢 30 代、男性
- 原因不明の心嚢水の貯留のため精査
- アスベスト暴露歴不明

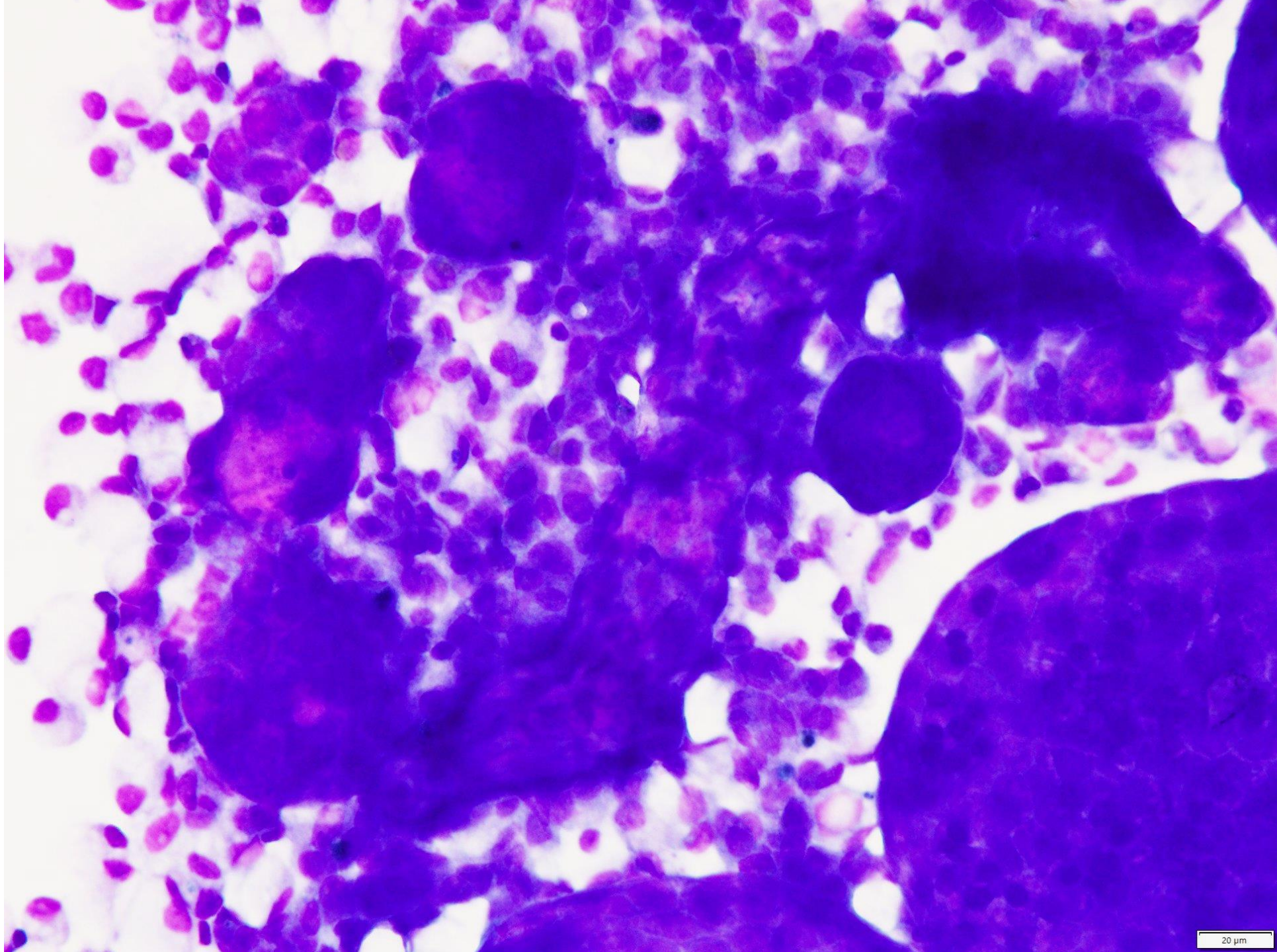


50  $\mu$ m

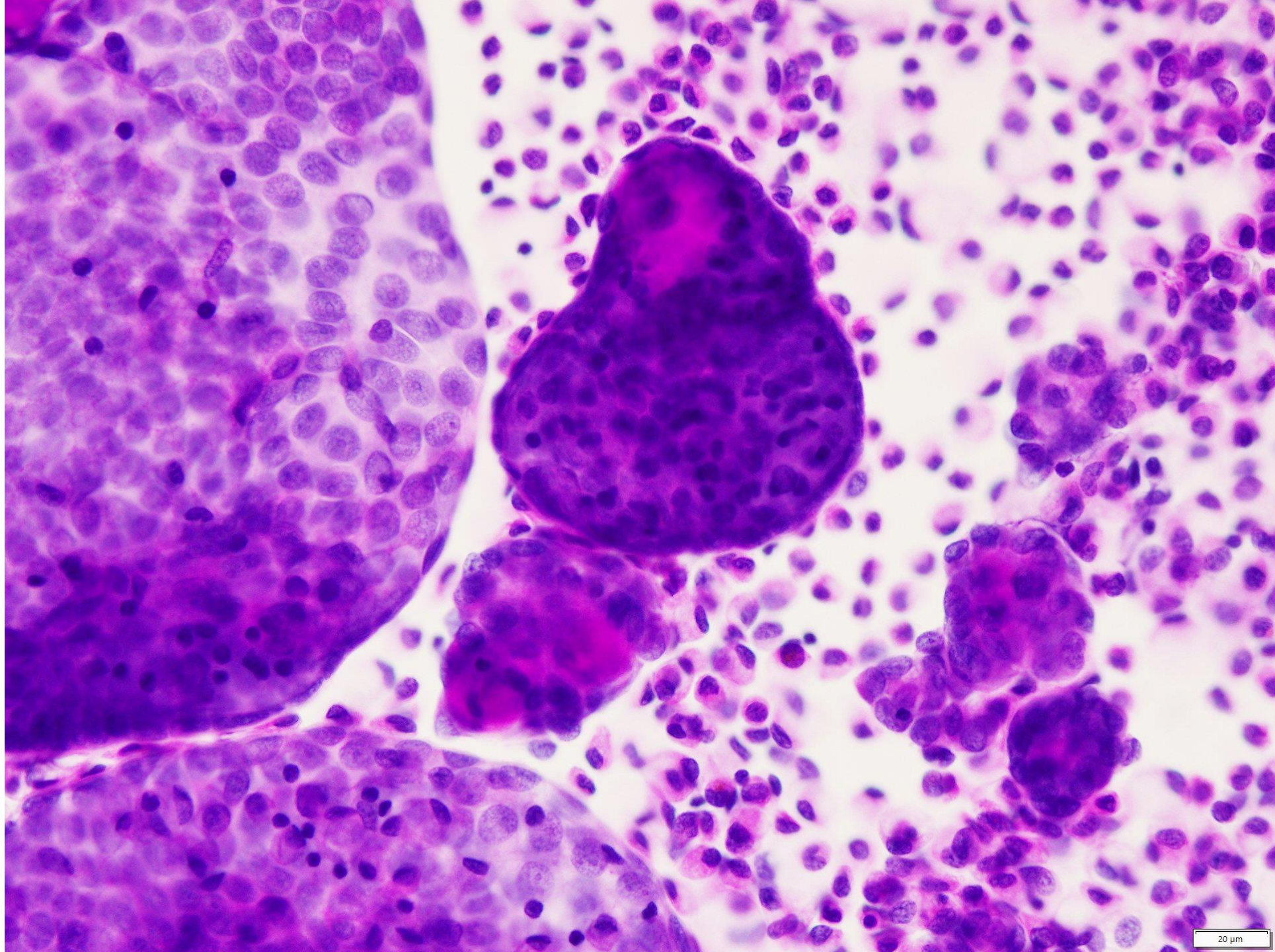


20 μm





20  $\mu$ m



# 選擇肢

1. 反應性中皮細胞
2. 中皮腫
3. 腺癌