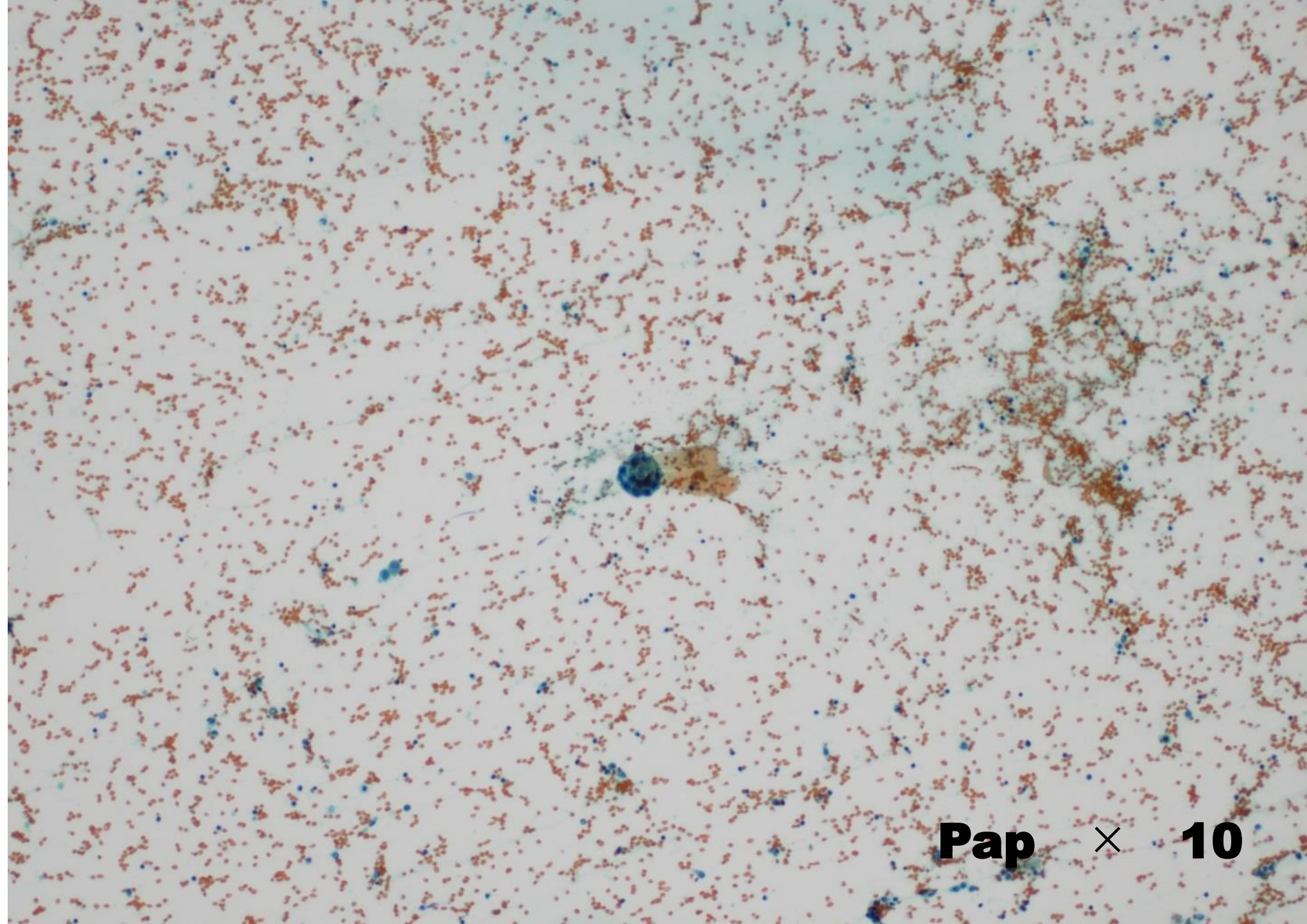
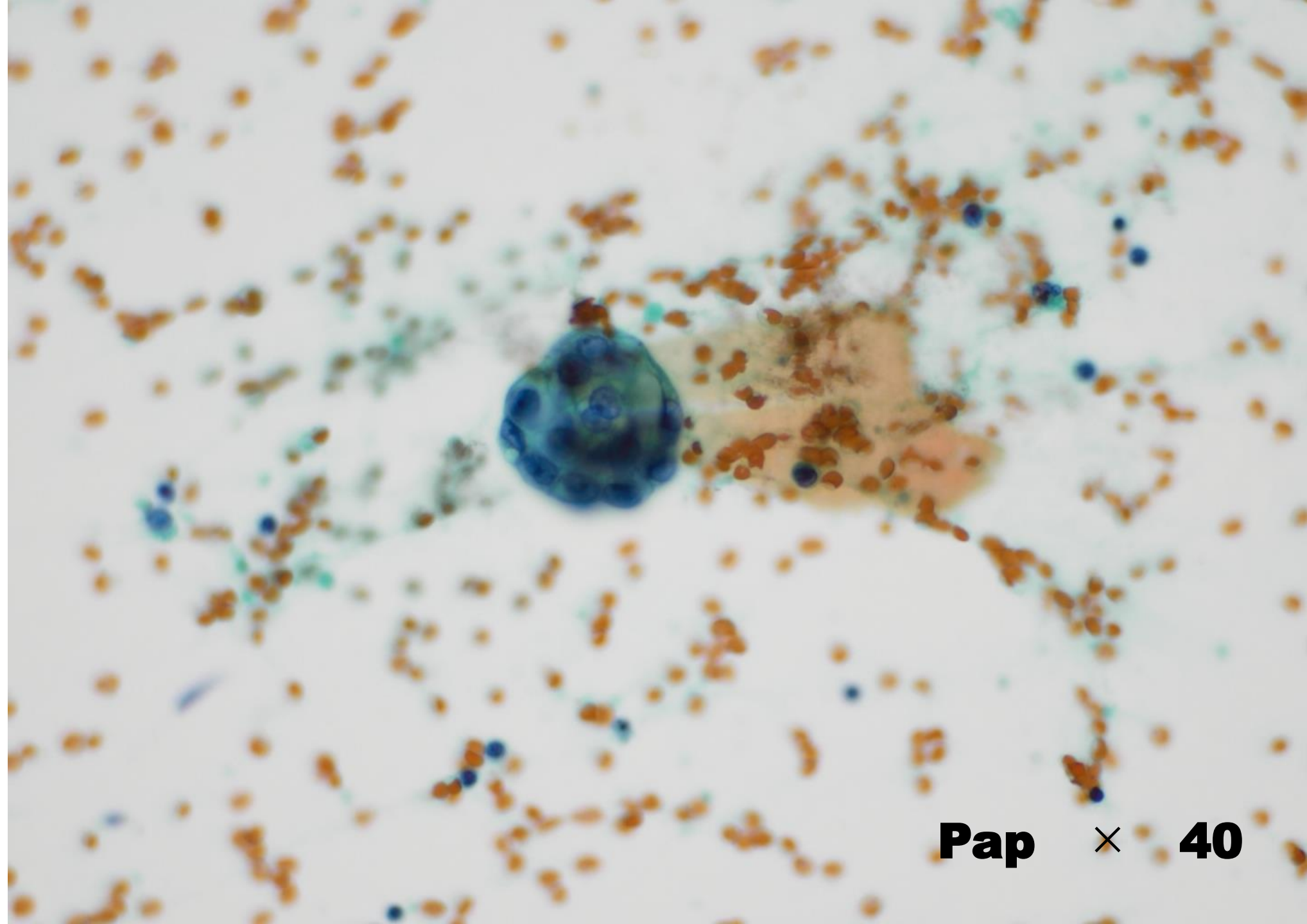


症例（腹水）

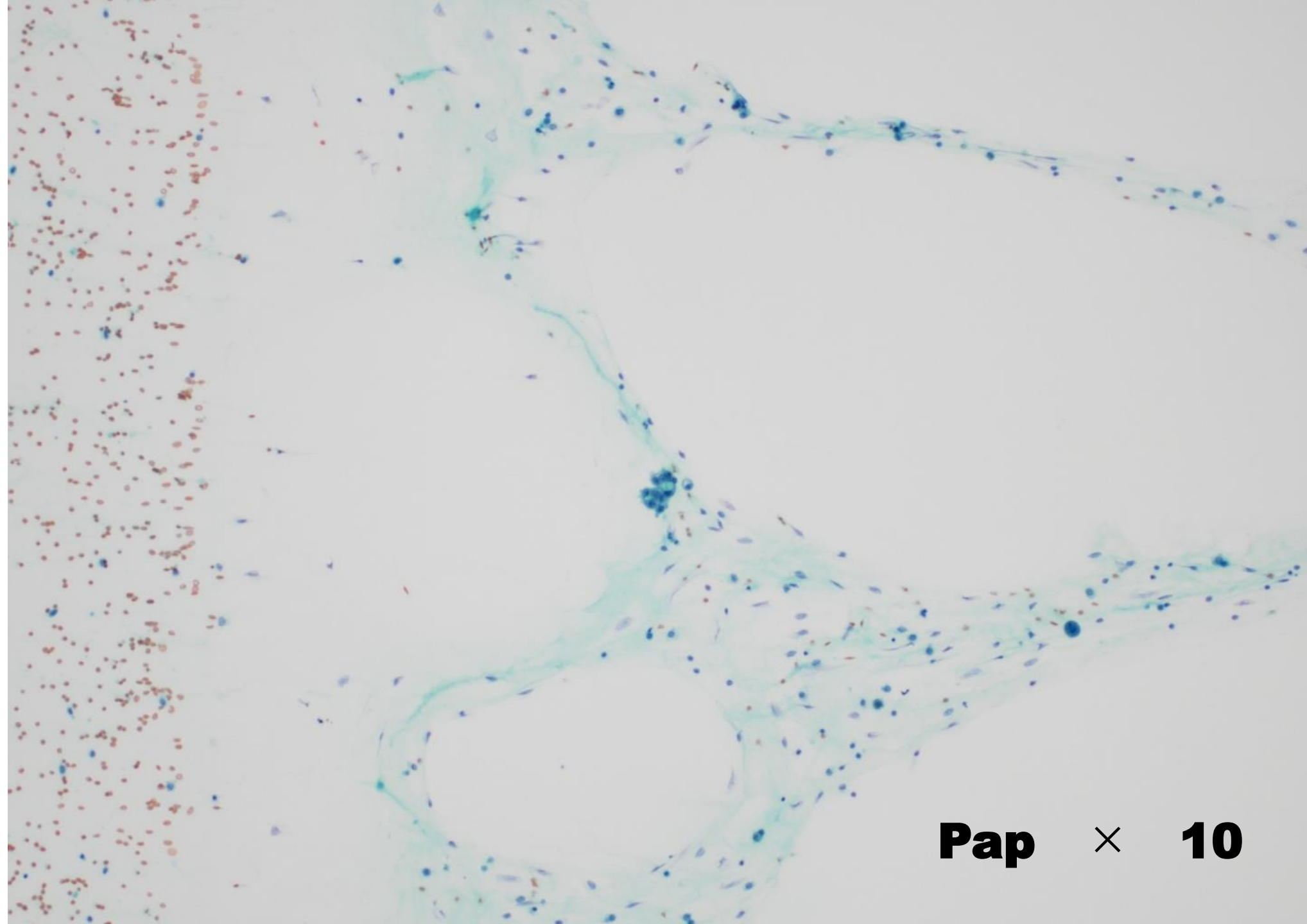
- ・ 70代男性
- ・ 主訴：肺炎 胸水貯留
- ・ **CT**上で腹水貯留
- ・ 膿胸/癌性胸膜炎疑い
- ・ アスベスト暴露歴不明



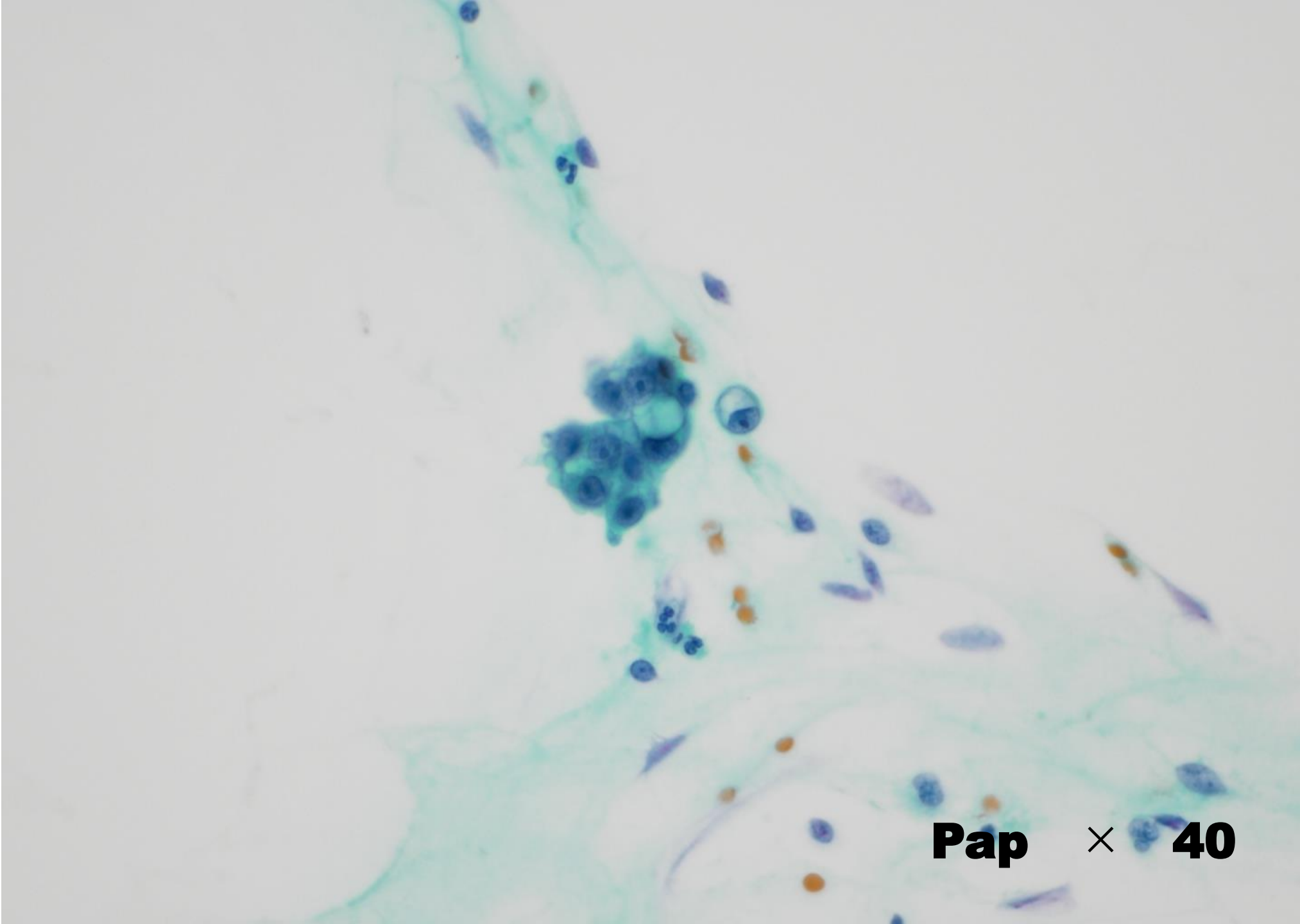
Pap × 10



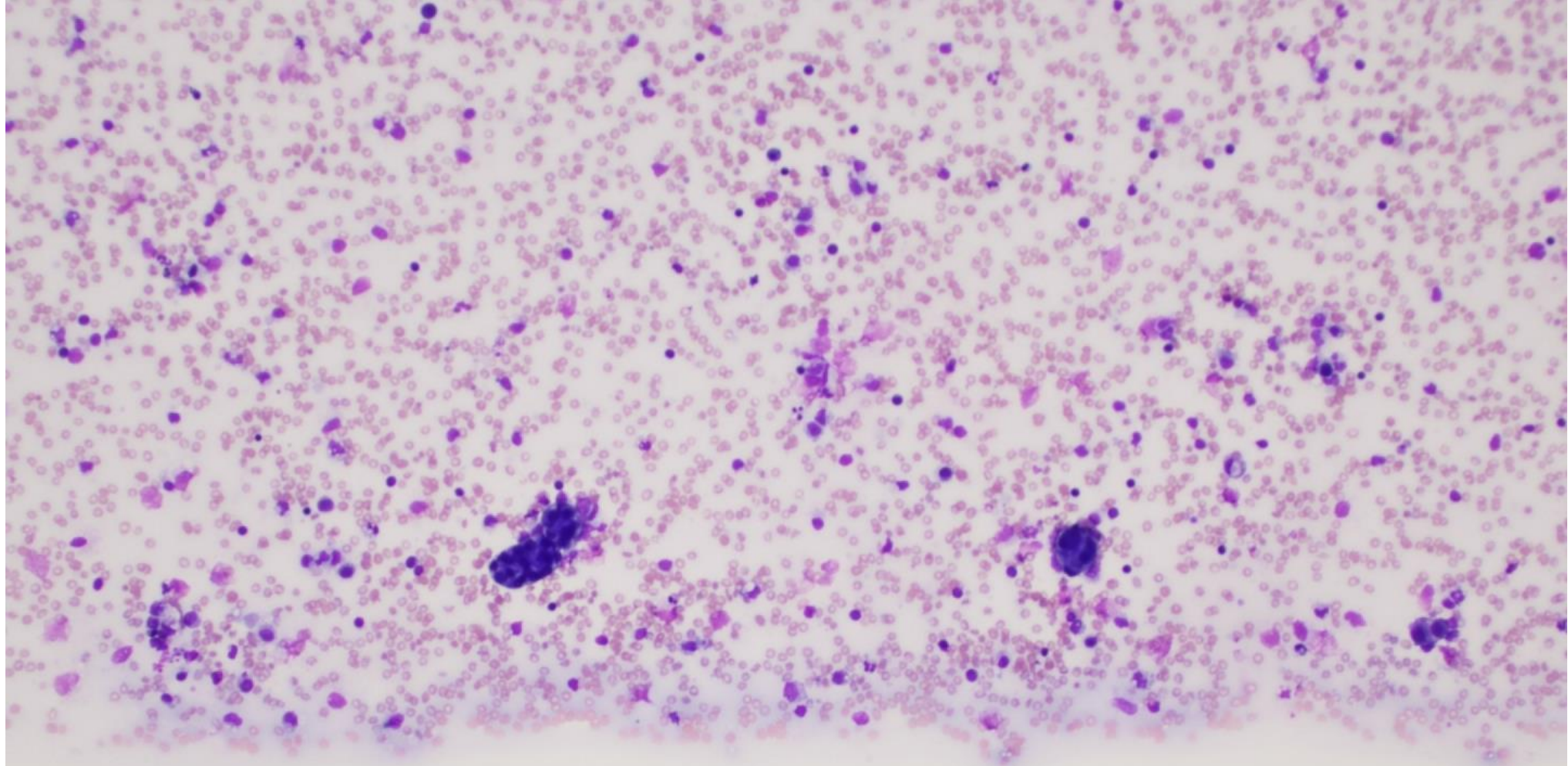
Pap × 40



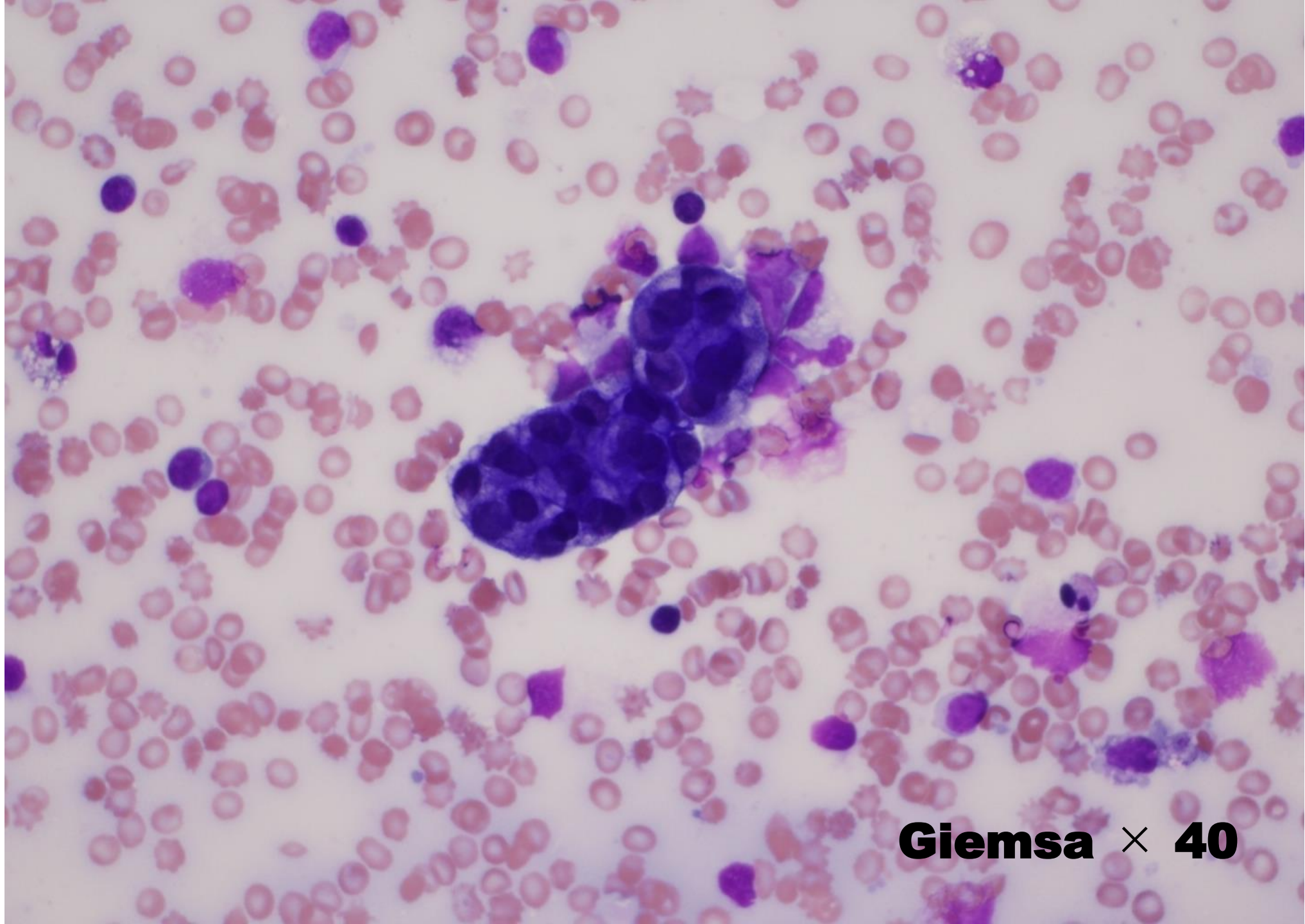
Pap × 10



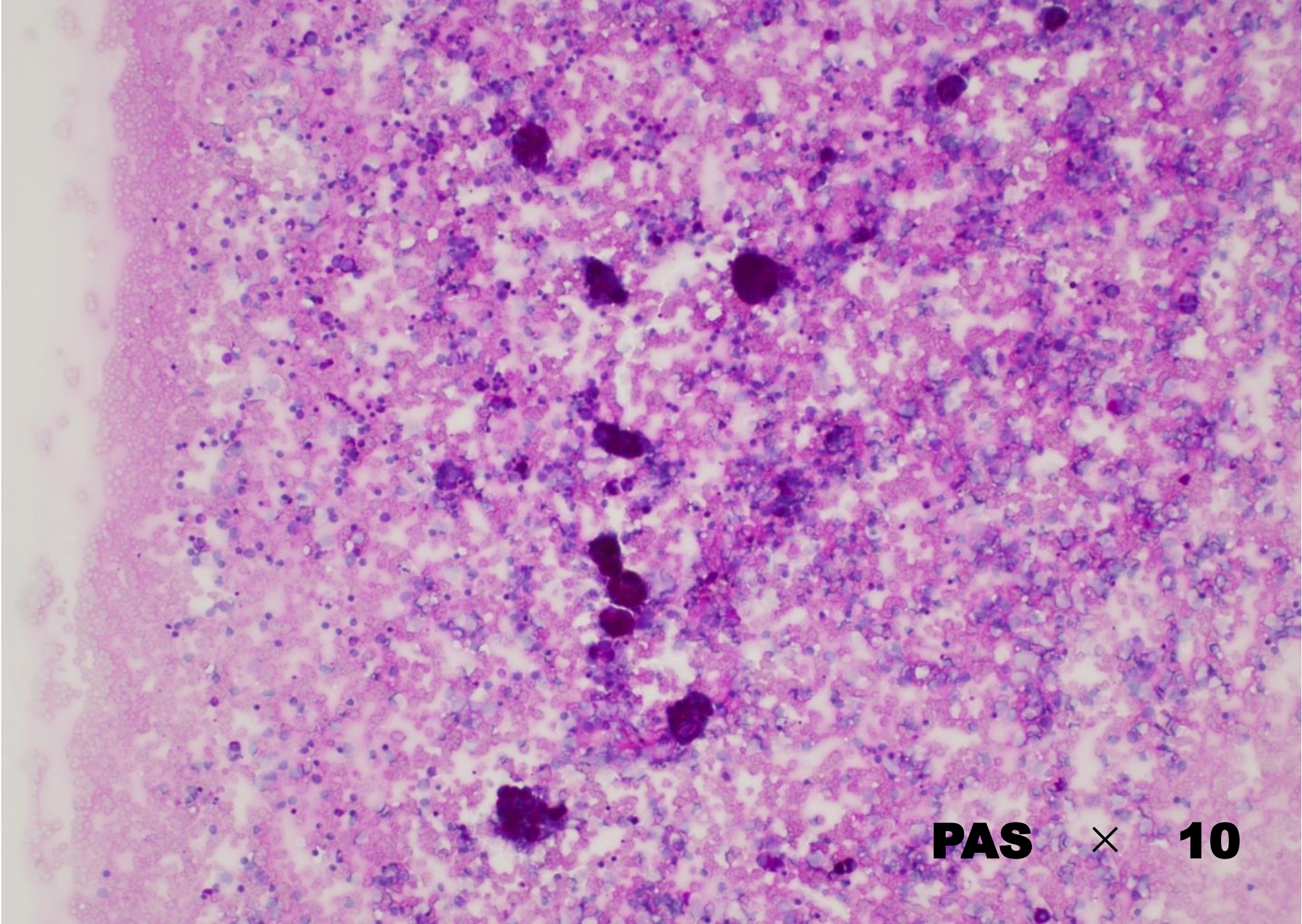
Pap × 40



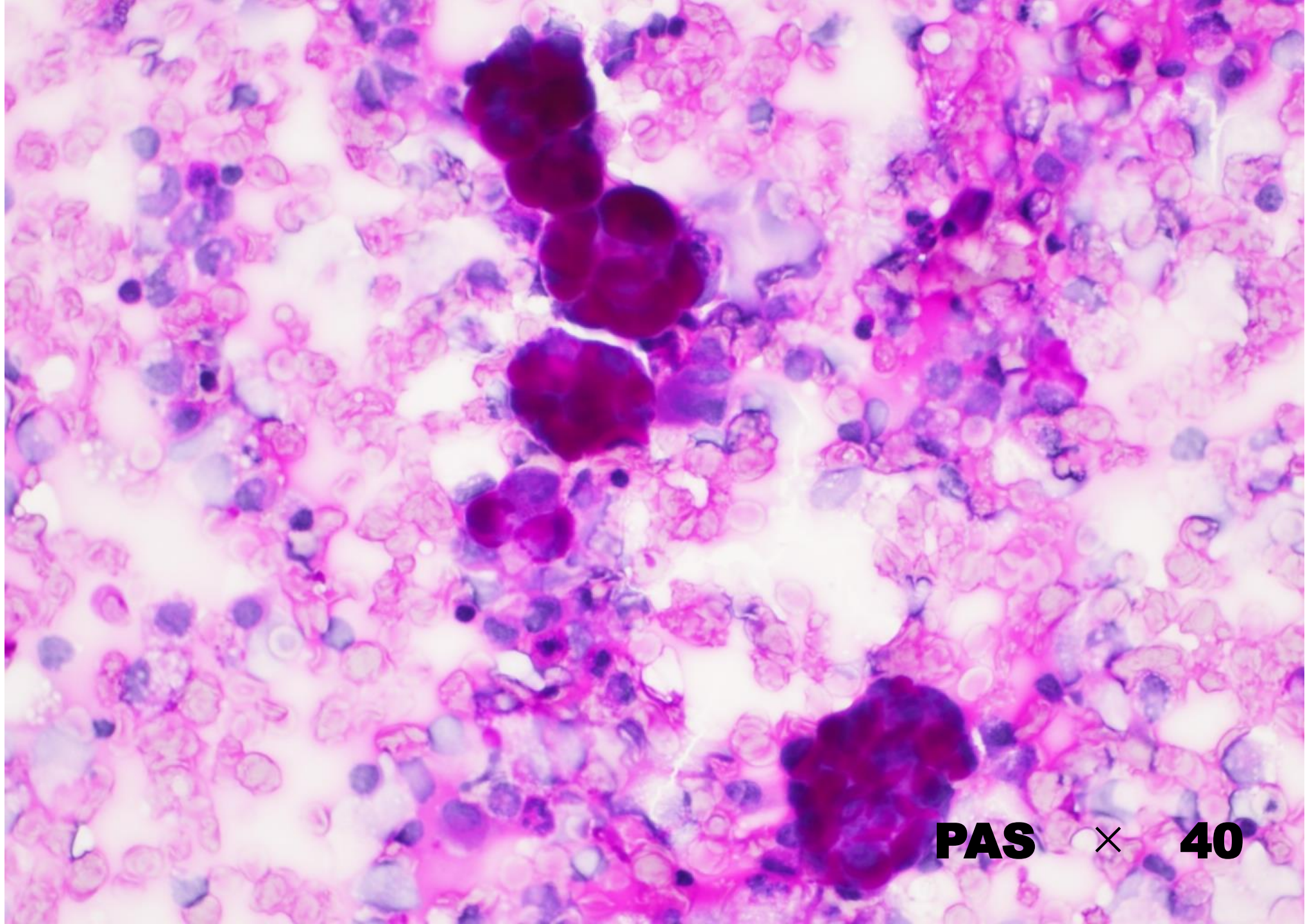
Giemsa × 10



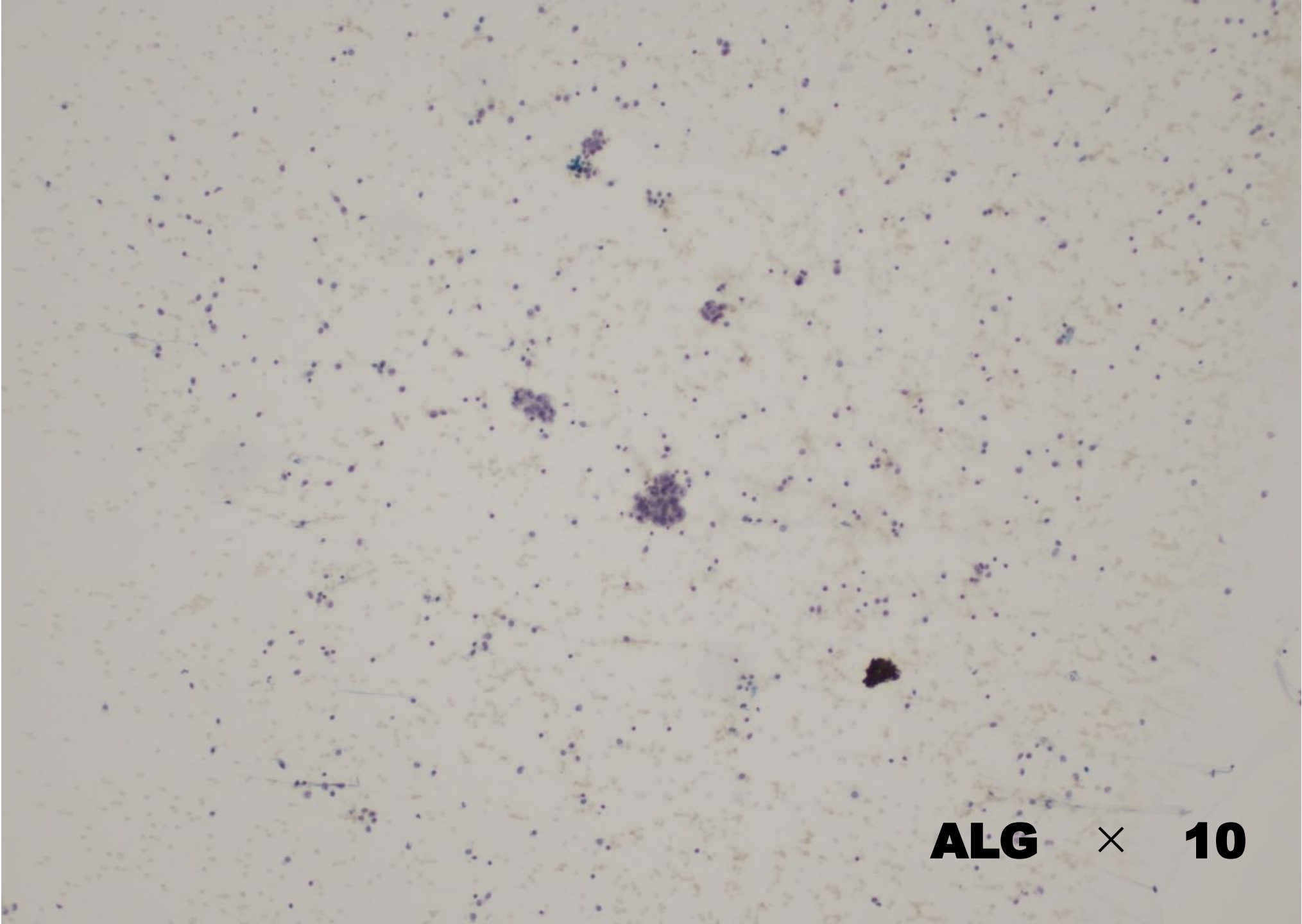
Giemsa × 40



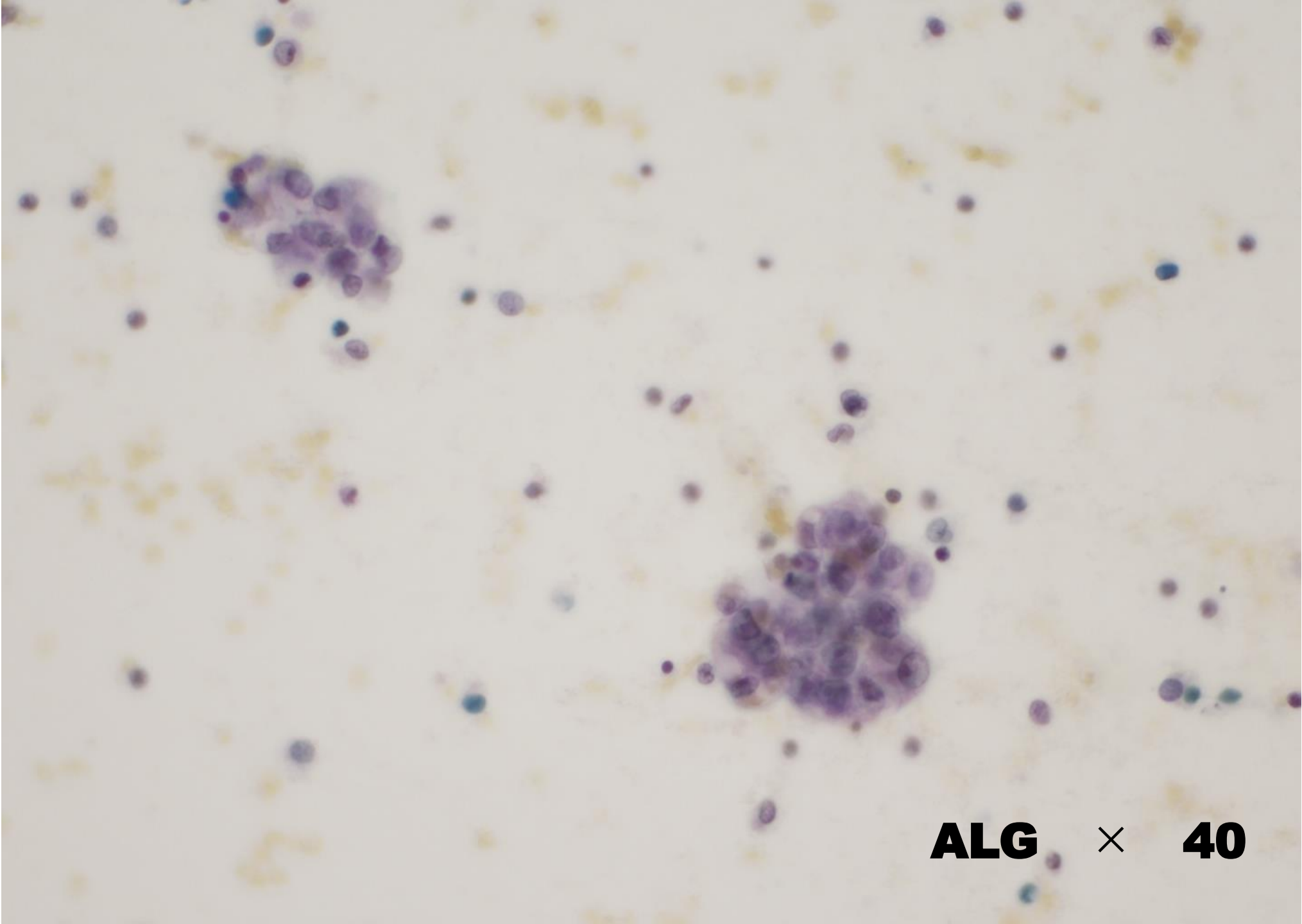
PAS × 10



PAS × **40**



ALG × 10



ALG × **40**

選擇肢

1. 反應性中皮細胞
2. 中皮腫
3. 腺癌